INNOVATIONS

A CLINICAL EXCHANGE ON ADVANCES IN ORTHOPAEDICS

VOLUME 2

ISSUE 1

02 Equinoxe® rTSA Platform Shoulder System Design Rationale

09 Evaluation of the Accuracy and Precision of a Next Generation Computer-Assisted Surgical System

26 Monobloc Revision Femoral Stem: First Cases

27 Revision of the Loose Glenoid Component in Anatomic Total Shoulder Arthroplasty

38 Periprosthetic Infection with a Focus on the Knee: Pathogenesis, Evaluation, and Treatment

43 Evaluation and Treatment of the Infected Shoulder Arthroplasty

49 The Preformed Spacers: From the Idea to the Realization of an Industrial Device

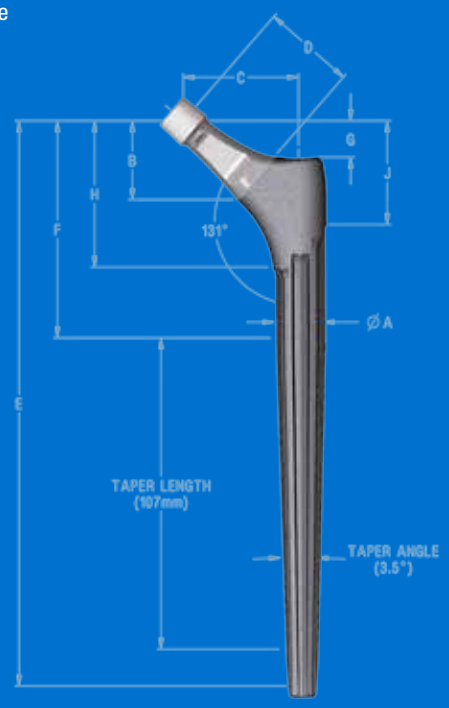

18

The Effect of Taper Angle and Spline Geometry on the Initial Stability of Tapered, Splined Modular Titanium Stems

Jeffery L. Pierson, MD, Scott R Small, MS, Jose A. Rodriguez. MD, Michael N. Kang, MD, Andrew H. Glassman, MD

EXACTECH, INC.

ICJR

GLOBAL | PERSONAL | PORTABLE

Make ICJR Your Source for Orthopaedic Education

GO TO www.ICJR.net TODAY

GLOBAL ICJR

REGISTER
for an ICJR Meeting!

Attend any one of our live events, including Global Congresses, CME Courses and Resident/ Fellow Programs.

PERSONAL ICJR

JOIN
our Global ICJR Community!

Interact with experts and colleagues on hot topics in orthopaedics, benefit from enhanced access to on-line content, and take advantage of discounted registration fees for ICJR Courses.

PORTABLE ICJR

INSTALL
the ICJR App!

Access a wealth of educational content anytime, anywhere from your computer or mobile device.

INNOVATIONS

A CLINICAL EXCHANGE ON ADVANCES IN ORTHOPAEDICS

VOLUME 2 | ISSUE 1

EDITORIAL

01 | Complexity Simplified | *Bill Petty, MD, Gary Miller, PhD*

SCIENTIFIC ARTICLES

02 | Equinoxe® rTSA Platform Shoulder System Design Rationale | *Christopher P. Roche, MS, MBA, Pierre-Henri Flurin, MD, Lynn Crosby, MD, Thomas W. Wright, MD, Joseph Zuckerman, MD*

09 | Evaluation of the Accuracy and Precision of a Next Generation Computer-Assisted Surgical System | *Laurent D. Angibaud, BS, Yifei Dai, PhD, Ralph A. Liebelt, MD, Bo Gao, PhD, Scott W. Gulbransen, Xeve S. Silver, BS*

18 | The Effect of Taper Angle and Spline Geometry on the Initial Stability of Tapered, Splined Modular Titanium Stems | *Jeffery L. Pierson, MD, Scott R Small, MS, Jose A. Rodriguez, MD, Michael N. Kang, MD, Andrew H. Glassman, MD*

27 | Revision of the Loose Glenoid Component in Anatomic Total Shoulder Arthroplasty | *Pierre-Henri Flurin, MD, Martin Janout, MD, Christopher P. Roche, MS, MBA, Thomas W. Wright, MD, Joseph Zuckerman, MD*

38 | Periprosthetic Infection with a Focus on the Knee: Pathogenesis, Evaluation, and Treatment | *Daniel C. Allison MD, MBA, FACS*

43 | Evaluation and Treatment of the Infected Shoulder Arthroplasty | *Daniel J. Hackett, Jr., MD, Lynn A. Crosby, MD*

CASE REPORTS

26 | Monobloc Revision Femoral Stem: First Cases | *Jose A. Rodriguez, MD, Michael Kang, MD*

COMMENTARY

49 | The Preformed Spacers: From the Idea to the Realization of an Industrial Device | *Renzo Soffiatti, PhD*

Editors
Bill Petty, MD | Exactech, Inc.
Gary Miller, PhD | Exactech, Inc.

Contributors
Daniel C. Allison, MD | Cedars-Sinai Sam Oschin Cancer Center
Lynn A. Crosby, MD | Georgia Regents Medical Center
Kenneth Egol, MD | NYU Hospital for Joint Diseases
Pierre-Henri Flurin, MD | Clinique du Sport Bordeaux-Mérignac
Andrew H. Glassman, MD | The Ohio State University Medical Center
Daniel J. Hackett, MD | Georgia Regents Medical Center
Martin Janout, MD | Northwest Orthopaedic Specialists
Michael N. Kang, MD | Insall-Scott-Kelly Institute for Orthopaedics and Sports Medicine
Ralph A. Liebelt, MD | Triangle Orthopaedic Associates
Jeffrey L. Pierson, MD | Joint Replacement Surgeons of Indiana Foundation, Inc.
Scott R. Small | Joint Replacement Surgeons of Indiana Foundation, Inc.
Renzo Soffiatti, PhD | Tecres, S.p.A.
Jose A. Rodriguez, MD | Lenox Hill Hospital
Thomas Wright, MD | University of Florida College of Medicine
Joseph D. Zuckerman | NYU Hospital for Joint Diseases

Managing Editor
Colleen Raccioppi, APR

Graphic Design
Sheryl Connor

Get In Touch with Us

Innovations features the latest solutions to the challenges orthopaedic surgeons face. Part technical journal and part clinician magazine, this publication facilitates surgeon-to-surgeon exchange on the tools and techniques that can improve patient outcomes.

Give us your feedback on this edition as well as read and share Innovations online at **www.exac.com/innovations**.

Exactech, Inc. • 2320 NW 66th Court • Gainesville, Florida 32653 USA

+1 800-EXACTECH (+1 800-392-2832) +1 352-377-1140 www.exac.com

Outcomes referenced in this publication are the results of a single surgeon's experience. Each patient must be evaluated and treated individually, and results will vary. Exactech, as a manufacturer of orthopaedic devices, does not practice medicine and is not responsible for recommending surgical techniques for use on particular patients. Clinician contributors are consultants to Exactech, Inc. and clinical studies were performed under the company's direction.

©2016 Exactech, Inc. | 710-02-00

Exactech **Medical** Education

2016 CALENDAR

Gain Exposure to the Latest Advances in Arthroplasty

SHOULDER

Mastering Glenoid Exposure, the Reverse Shoulder and the Challenging Glenoid

DATE	LOCATION	FACULTY
Fri., Jan. 29	Austin, Texas	David Collins, MD; Robert Fullick, MD; Scott Trenhaile, MD
Fri., Mar. 18	Phoenix, Ariz.	Matthew Hansen, MD; Raymond Klug, MD; Kaveh Sajadi, MD
Fri., May 13	New York, N.Y.	Pierre-Henri Flurin, MD Robert Fullick, MD; Curtis Noel, MD; Felix (Buddy) Savoie, MD; Thomas Wright, MD; Joseph Zuckerman, MD
Fri., June 3	Columbus, Ohio	Greg Bauer, MD; Stephen Maurer, MD; Rick Papandrea, MD
Fri., July 15	San Francisco, Calif.	Emilie Cheung, MD; Raymond Klug, MD; Howard Routman, DO
Fri., Oct. 21	Indianapolis, Ind.	Douglas Lowery, MD; Stephen Maurer, MD; Moby Parsons, MD
Fri., Nov. 11	Tampa, Fla.	Brian Barnard, MD; Rahul Deshmukh, MD

SHOULDER, HIP & KNEE

Advanced Surgical Solutions for Shoulder, Hip and Knee Arthroplasty

DATE	LOCATION	FACULTY	
Fri.-Sat., Feb. 12-13	Miami, Fla.	**SHOULDER:** Kevin Farmer, MD; Douglas Lowery, MD; Ryan Simovitch, MD **HIP:** Hodari Brooks, MD; Barton Harris, MD; Joseph Locker, MD **KNEE:** Barton Harris, MD; Raymond Robinson, MD	
Fri.-Sat., April 8-9	Washington, D.C.	**SHOULDER:** Lynn Crosby, MD; Howard Routman, DO; Mark Scarborough, MD; Ryan Simovitch, MD **HIP:** Andrew Glassman, MD; Jeffery Pierson, MD; Bernard Stulberg, MD **KNEE:** Daniel Allison, MD; Bernard Stulberg, MD	REVISION FOCUS
Fri.-Sat., Aug. 26-27	Chicago, Ill.	**SHOULDER:** David Collins, MD; Kevin Farmer, MD; Scott Trenhaile, MD **HIP:** John Aldridge, MD **KNEE:** Michael Cross, MD; Craig Morrison, MD	

OTHER MEDICAL EDUCATION OPPORTUNITY

International Shoulder Masters Course*
Thurs.- Sat., Apr. 7-9 • Bordeaux France
by invitation

REGISTRATION INFORMATION
To learn more or to register for courses, please visit:
www.exac.com/courses

Additional course(s) to be announced. Courses and faculty subject to change.

COMPLEXITY SIMPLIFIED

Bill Petty, MD
Exactech Executive Chairman

Gary Miller, PhD
Exactech Executive Vice President, Research and Development

Look for this symbol throughout this issue for educational opportunities to get hands-on experience with primary and revision prostheses.

Since we began Exactech more than 30 years ago, our goal has been to help surgeons worldwide make patients more mobile. Our innovations have been designed with a singular purpose: to improve patient outcomes.

However, even with the best implant systems in the hands of the best surgeons, revisions are inevitable due to trauma, oncology and infection or even implant failure. By their very nature, revision cases are challenging, so one of Exactech's current areas of focus is to create solutions that make this complexity simplified.

We partner with and listen to surgeon collaborators to advance the efficiency of our instruments and the efficacy of our implant systems because it's our goal to make each case go exactly as planned. As we prepare to introduce new products for revision arthroplasty, we are incredibly proud to have assembled clinician design teams of the highest caliber, some of whom are authors in this issue of *Innovations*.

This edition includes design philosophies for reverse total shoulder arthroplasty (rTSA) that may mitigate common complications and failure modes (p. 02) as well as an evaluation of how accuracy and precision of computer-assisted surgery affects long-term clinical success in total knee arthroplasty (TKA) (p. 09). On page 18, surgeons examine the effects of two major design elements of tapered, splined, modular titanium stems for femoral revision THA and review early outcomes with the Alteon® Monobloc Revision Femoral Stem (p. 26). Reconstructive options for treating a loose glenoid option in anatomic total shoulder arthroplasty (aTSA) are discussed on page 27. Evaluation and treatment infected TKA (p. 38) and total shoulder arthroplasty (TSA) (p. 43) are covered in this issue, as well as insights into pre-formed antibiotic spacer designs (p. 49).

We hope you enjoy *Innovations* and find this issue both interesting and beneficial. Thank you for being an Exactech partner. •

LETTER TO THE EDITORS

Join our email list for future electronic issues of *Innovations*
www.exac.com/innovations

You are invited to give us your feedback and to subscribe to supplementary email content. **www.exac.com/innovations**

Here's what one of your colleagues had to say about *Optimizing Polyethylene Materials to the Application: When It Comes to Manufacturing Methods, Hips Are Not Knees* in our last electronic issue:

> *"Wonderful editorial. The main reason I use Exactech's knee is this exact story. I vividly remember being in a meeting 20 years ago hearing from an expert that crosslinked polyethylene was good for hips and bad for knees. The reason most big companies don't use net compression molded poly is COST. Plain and simple. Great work."*
>
> *–H. Morton Bertram, MD • Bertram Total Joint Center*

EQUINOXE® RTSA PLATFORM SHOULDER SYSTEM DESIGN RATIONALE

Christopher P. Roche, MS, MBA
Exactech, Inc.

Pierre-Henri Flurin, MD
Clinique de Sport Bordeaux-Mérignac

Lynn Crosby, MD
Georgia Regents Medical Center

Thomas W. Wright, MD
University of Florida College of Medicine

Joseph Zuckerman, MD
NYU Hospital for Joint Diseases

www.exac.com/courses

May 13 | Mastering Glenoid Exposure, the Reverse Shoulder and the Challenging Glenoid **| New York, NY**

The Equinoxe® reverse shoulder was first implanted in March 2007 (Figure 1). The primary development goal was to significantly reduce the complication rates reported with all previous reverse shoulder arthroplasty (rTSA) prosthesis designs, including: scapular notching, instability/dislocation, aseptic glenoid and humeral loosening, lack of active internal/external rotation, acromial/scapular fractures, and deltoid-fatigue.[1-3] Additional concerns included difficulty in revisions, bone conservation, and lack of compatibility between primary and revision components. Many of these complications, failure modes, and concerns may be inter-related and a function of non-optimized prosthesis design. The following explains the specific design rationale and presents some validation tests that demonstrate successful mitigation of these complications.

DESIGN GOAL #1: REDUCE THE SCAPULAR NOTCHING RATE

Scapular notching is initiated by repetitive mechanical humeral liner impingement on the scapular neck and inferior glenoid.[3] Relative to the Sirveaux grading scale,[3] the geometric limit of impingement with most prosthesis designs is grade 2 (i.e., to the inferior glenoid baseplate screw). However, scapular notching has been documented to be progressive[4-5] beyond these limits of impingement (e.g. Sirveaux grades 3 or 4) due to the biologic response. Scapular notching has recently been demonstrated to negatively impact clinical outcomes[3,6-8] and negatively impact glenoid fixation,[9] which is in stark contrast to initial reports.[10-11]

By minimizing humeral liner impingement, scapular notching can be minimized. To this end, a 3-D computer impingement model was developed prior to design of the Equinoxe shoulder to analyze 32 different geometric permutations of the Grammont reverse shoulder by independently varying humeral neck angle (7 angles: 135-165°), humeral liner constraint (5 constraints: 0.25-0.3), glenosphere thickness (7 thicknesses: 18-24mm), glenosphere diameter (6 diameters: 34-44mm), and inferior glenoid offset (7 offsets: 0-6mm inferiorly).[12-15] Each design parameter was independently evaluated to identify its role in minimizing scapular impingement, maximizing overall

Figure 1. Equinoxe Reverse Shoulder

Figure 2. Equinoxe Glenoid Baseplate

range of motion (ROM), and maximizing "jump" distance. Specifically, three glenosphere sizes (38x21, 42x23, and 46x25mm) with a humeral neck angle of 145°, a curved-back glenoid baseplate with a 4mm superiorly offset cage peg, and different combinations of humeral liner were designed.

The clinical results of these designs have been encouraging. A recent radiographic study demonstrated the Equinoxe to have a scapular notching rate of 13.2 percent in 151 patients at a mean follow-up of 28.3 ± 5.7 months, with only 2.6 percent grade 2 notches and no grade 3 or 4 notches.[16] Another large scale radiographic study demonstrated that 26 of 256 patients (10.2 percent) had a scapular notch, where 38, 42, and 46mm glenospheres had a notching rate of 14.2 percent, 4.4 percent, and 0 percent, respectively at an average follow-up of 22.2 ± 8.7 months.[15] These results represent a significant reduction in the reported scapular notching rate of the Grammont design, which has an average reported scapular notching rate of 68.2 percent.[1-4,7,11,17-18]

DESIGN GOAL #2: REDUCE THE ASEPTIC GLENOID LOOSENING RATE

Aseptic glenoid loosening was the historical failure mode of pre-Grammont reverse shoulder designs that did not utilize a hemispherical glenosphere to minimize torque on the glenoid fixation surface.[1,19-20] The Equinoxe rTSA leveraged the Grammont clinical history by maintaining the center of rotation (CoR) near the face of the native glenoid and incorporating the optimization analysis recommendations for ideal CoR placement 2mm lateral to the native glenoid. To neutralize this slightly increased torque on the fixation interface, the baseplate surface contact area with the native glenoid was increased by changing the shape, size, and backside curvature from the circular 29mm diameter flat-back Grammont design. Additionally, by minimizing humeral liner impingement, polyethylene wear was reduced; thereby reducing particles that are the primary osteolytic agents in aseptic loosening.[21]

The Equinoxe baseplate is an oval 25x34mm curve-back design (Figure 2). The design evolution of the glenoid prosthesis with anatomic shoulder arthroplasty (aTSA) started with circular profile devices that ultimately converged to an anatomic pear-shaped profile device. For the same reasons, the Equinoxe baseplate is superiorly elongated in the primary loading direction to neutralize any destabilizing action of the deltoid. By superiorly elongating the baseplate, the surface contact area is increased, affording the possibility to reduce the anterior/posterior width from 29mm to 25mm and facilitate a more anatomic fit in smaller glenoids.[22] Recent work evaluated eight baseplate designs and demonstrated that the Equinoxe had the largest surface contact area on the backside of the plate, 20 percent larger than the next largest baseplate.[23] The screw hole pattern is maximized by positioning the screws to the edge of this enlarged periphery and increasing the number of screw options from four to six to provide surgeons with additional intra-operative flexibility. To maximize the length of screws used to achieve fixation, poly-axial compression screws that provide 20° of angular variability are utilized and each screw is locked with a cap to prevent

Figure 3. Equinoxe rTSA Baseplates; from left to right: Standard, 8° Posterior Augment, 10° Superior Augment, +10mm Extended Cage Peg, 10° Superior/8° Posterior Augment Baseplates

backing out; the importance of angular screw variability was emphasized in a recent study with a competitive rTSA design.[24]

The Equinoxe baseplate is 2 inch diameter curved backside geometry closely matches the native glenoid curvature preserving cortical and cancellous bone, and increases cortical bone contact to maximize baseplate support.[22] Recent work quantified the cortical and cancellous glenoid bone removed by three different commercially-available rTSA prosthesis designs and demonstrated the Equinoxe removed the least glenoid bone and had the most cortical, cancellous, and overall glenoid bone surface contact area relative to the Depuy Delta III and DJO RSP.[25]

While preserving glenoid bone, achieving optimal screw length/placement, and maximizing baseplate surface contact are all important contributors to fixation, these are but a few of the variables that establish initial fixation. ASTM Standard F2028-1427 was developed to objectively evaluate and quantify the fixation of rTSA prostheses before and after a clinically relevant cyclic loading pattern. The ASTM rTSA glenoid loosening test has previously demonstrated differences in fixation between screw configurations,[27] medialized/lateralized CoR,[28-30] glenoid baseplate designs,[29-30] scapular defects and wear patterns,[9, 32] and different densities of substrates.[27,30-31] Two recent studies quantified the fixation of six different commercially available rTSA prostheses in both low and high density polyurethane blocks.[30-31] These studies demonstrate that the Equinoxe and Delta III devices had significantly better glenoid fixation than each of the Zimmer, DJO, and BIO-RSA devices. Additionally, catastrophic failure was observed in at least one of each of the Zimmer, DJO, and BIO-RSA test components during cyclic loading; no failure occurred in either of the Equinoxe or Delta III devices.[30-31] While designs with a more lateralized CoR generally performed poorly, other factors may impact fixation. The Equinoxe design performed significantly better than the Zimmer device, despite each having identical 2mm lateralized CoRs. Thus, subtle differences in baseplate design can significantly impact fixation.

Aseptic glenoid loosening is more likely in eroded scapular morphologies. Generally, surgeons eccentrically ream an eroded glenoid to correct the defect. Eccentric reaming medializes the joint line and removes good, non-worn glenoid bone to correct the defect, which may compromise fixation.[32-33] To conserve glenoid bone, increase prosthesis surface contact area with cortical bone, and to better restore the native joint line when performing rTSA in eroded scapular morphologies,[25,32,34] the Equinoxe system provides unique augmented glenoid baseplates (Figure 3).

DESIGN GOAL #3: REDUCE THE INSTABILITY RATE & IMPROVE RESTORATION OF ACTIVE ROTATION

By minimizing humeral liner impingement with the scapula, the lever-out mechanism can be eliminated and the instability rate can be potentially reduced. Restoring the lateral position of the humerus may reduce the instability rate and also improve active internal/external rotation.[1,10,21,34-42] The Grammont reverse shoulder medializes the humerus to such a degree that the rotator cuff is under-tensioned and

Figure 4. Impact of Humeral Medial/Lateral Positioning on Rotator Cuff Tensioning with TSA; from left to right: Anatomic Shoulder, Grammont, DJO RSP, Exactech Equinoxe reverse shoulders

deltoid wrapping around the greater tuberosity is reduced.[34,36-42] By lateralizing the greater tuberosity to a more anatomic location, the Equinoxe can better restore rotator cuff muscle tension and deltoid wrapping (Figure 4).[34,36-42]

A virtual shoulder model was developed to quantify muscle lengths,[33-34,36,41-43] moment arms,[36-39,43] and deltoid wrapping of different rTSA prosthesis designs,[34,39,41-44] implanted using a variety of implantation techniques[41], and in a variety of different glenoid morphologies.[33-34] One recent study compared the muscle lengths and deltoid wrapping associated with the Depuy Delta III, DJO RSP, and Equinoxe designs along with the BIO-RSA technique. These results objectively demonstrated that designs and surgical techniques which resulted in more lateral humeral positioning were associated with more deltoid wrapping and better tensioning of the rotator cuff.[41] The Delta III positioned the humerus most medially and shortened the rotator cuff by as much as 45.3 percent. We theorize that this magnitude of muscle shortening may be the primary mechanism for the limited improvements in active internal and external rotation reported with that prosthesis. The Equinoxe had the most lateral humeral position, most deltoid wrapping, and best restored the anatomic rotator cuff tension relative to the other rTSA prostheses evaluated.[41] These observations related to more anatomic rotator cuff tensioning and deltoid wrapping are likely responsible for the favorable ROM and clinical outcomes reported with the Equinoxe in a recent multi-center clinical study[44] and compared favorably to that reported[1,3,5,8,11,35,45] for other rTSA designs.

DESIGN GOAL #4: REDUCE THE LESSER REPORTED COMPLICATIONS

There are other less common complications of rTSA. Aseptic humeral loosening is rare with aTSA.[46] Given that loading of rTSA is generally of less magnitude and similar direction,[47-48] aseptic humeral loosening should also be rare with rTSA. We theorize that aseptic humeral loosening is reported more commonly with rTSA[21,46] due to non-optimal humeral stem design and humeral implantation techniques which resect and/or spherically ream too much of the proximal humerus and create less rotationally-stable constructs than occurs with aTSA. Aseptic humeral loosening is further exacerbated when polyethylene particles illicit a biologic response.[21] In the Equinoxe reverse shoulder design, aseptic humeral loosening was mitigated by utilizing the same rotationally-stable humeral stem and implantation technique of the clinically successful Equinoxe aTSA system. Additionally, by minimizing scapular notching, polyethylene particles are reduced. A recent computer analysis quantified the humeral bone removed by three different commercially-available designs and demonstrated the Equinoxe removed the least overall humeral bone relative to the Depuy Delta III and DJO RSP.[25]

Acromial/scapula fractures and the phenomenon of deltoid fatigue are other less common complications that are not well understood. Acromial/scapula fractures have been reported to propagate from superior baseplate screws.[49] We theorite the majority of these fractures are bone fatigue injuries due to repetitive overloading by the deltoid. The Equinoxe reverse shoulder CoR is maintained near the

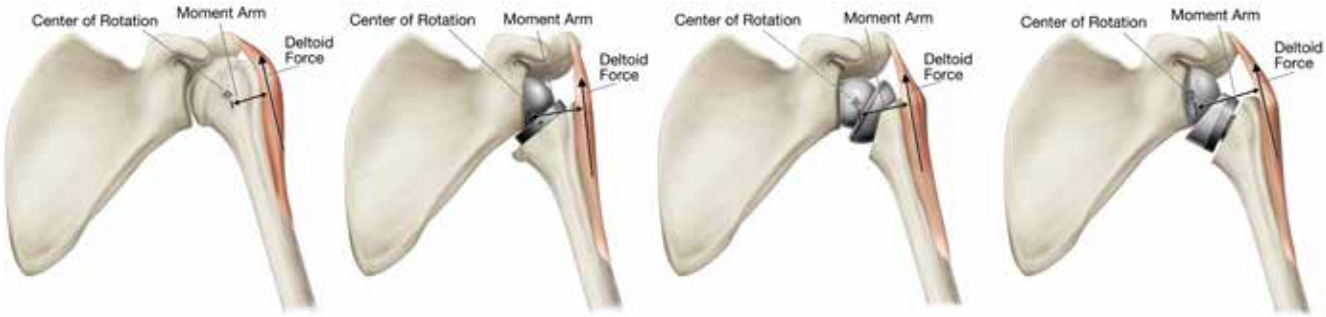

Figure 5. Impact of Position of the Center of Rotation and Humerus on Deltoid Abductor Moment Arm & Deltoid Wrapping; from left to right: Anatomic Shoulder, Grammont, DJO RSP, Exactech Equinoxe reverse shoulders

native glenoid to increase the deltoid abductor moment arm and minimize the necessary force generated by the deltoid to elevate the arm. By maintaining an efficient deltoid, the risk of stress-fractures and deltoid over-loading are minimized (Figure 5). It should be noted that there are a variety of rTSA design philosophies; with one philosophy lateralizing the CoR by up to 1cm to minimize scapular notching. While increasing glenosphere thickness does reduce impingement,[12-13] it also increases the torque on the glenoid fixation surface and reduces the deltoid abductor moment arm, which increases the force required by the deltoid.[36,38,39,50-51] A recent clinical study using a lateralized CoR rTSA design reported a 10.2 percent acromial/scapular fracture rate.[52] This rate is significantly higher than that reported with the Grammont and other medialized CoR rTSA prostheses[46,49] and suggests that subtle design changes can have adverse clinical consequences.

DESIGN GOAL #5: DESIGN A MORE REVISION-FRIENDLY, BONE CONSERVING SYSTEM

Additional opportunities were identified in the Equinoxe rTSA to improve efficacy in revisions and conserve bone through better design. On the humeral side, the procedure was simplified by utilizing the same ream-broach humeral stem technique used with the Equinoxe aTSA system (rather than a non-standard 155° humeral neck cut utilized by the Grammont which also spherically reams the proximal humerus). Using the same humeral component for aTSA and rTSA allows standardizing many humeral instruments, reduces the number of trays needed and permits surgeons to leverage their existing training and surgical experiences. Crosby et al. reported numerus benefits of retaining the same humeral stem during revisions.[53] By comparing revisions of platform humeral stems that were retained vs. non-platform humeral stems that were removed, revisions of platform humeral stems resulted in significantly less operating room time, less blood loss, and less overall procedure cost.[53] On the glenoid side, many patients receiving rTSA in revision may have an implanted pegged or keeled glenoid. The size and position of the superiorly offset cage peg on the Equinoxe baseplate was designed to fill the central bone defect left by the explanted glenoid implant. The six screw-hole base plate allows appropiate positioning relative to the explanted glenoids to ensure that multiple options are available to achieve fixation. •

REFERENCES

1. **Boileau P, Watkinson D, Hatzidakis AM, Hovorka I.** Neer Award 2005: The Grammont reverse shoulder prosthesis: results in cuff tear arthritis, fracture sequelae, and revision arthroplasty. *J Shoulder Elbow Surg.* 2006 Sep-Oct;15(5):527-40.

2. **Guery J, Favard L, Sirveaux F, Oudet D, Mole D, Walch G.** Reverse total shoulder arthroplasty. Survivorship analysis of eighty replacements followed for five to ten years. *J Bone Joint Surg Am.* 2006 Aug;88(8):1742-7.

3. **Sirveaux F, Favard L, Oudet D, et al.** Grammont inverted total shoulder arthroplasty in the treatment of glenohumeral osteoarthritis with massive rupture of the cuff. Results of a multicentre study of 80 shoulders. *J Bone Joint Surg Br.* 2004 Apr;86(3):388-95.

4. **Lévigne C, Garret J, Boileau P, Alami G, Favard L, Walch G.** Scapular notching in reverse shoulder arthroplasty: is it important to avoid it and how? *Clin Orthop Relat Res.* 2011 Sep;469(9):2512-20.

5. **Lévigne C, Boileau P, Favard L, Garaud P, Molé D, Sirveaux F, Walch G.** Scapular notching in reverse shoulder arthroplasty. *J Shoulder Elbow Surg.* 2008 Nov-Dec;17(6):925-35.

6. **Sadoghi P, Leithner A, Vavken P, Hölzer A, Hochreiter J, Weber G, Pietschmann MF, Müller PE.** Infraglenoidal scapular notching in reverse total shoulder replacement: a prospective series of 60 cases and systematic review of the literature. BMC Musculoskelet Disord. 2011 May 19;12:101. doi: 10.1186/1471-2474-12-101.

7. **Simovitch RW, Zumstein MA, Lohri E, Helmy N, Gerber C.** Predictors of scapular notching in patients managed with the Delta III reverse total shoulder replacement. *J Bone Joint Surg Am.* 2007 Mar;89(3):588-600.

8. **Stechel A, Fuhrmann U, Irlenbusch L, Rott O, Irlenbusch U.** Reversed shoulder arthroplasty in cuff tear arthritis, fracture sequelae, and revision arthroplasty. Acta Orthop. 2010 Jun;81(3):367-72.

9. **Roche CP, Stroud NJ, Martin BL, Steiler CA, Flurin PH, Wright TW, DiPaola MJ, Zuckerman JD.** The impact of scapular notching on reverse shoulder glenoid fixation. *J Shoulder Elbow Surg.* 2013 Jul;22(7):963-70. doi:10.1016/j.jse.2012.10.035.

10. **Boileau P, Watkinson DJ, Hatzidakis AM, Balg F.** Grammont reverse prosthesis: design, rationale, and biomechanics. *J Shoulder Elbow Surg.* 2005 Jan-Feb;14(1Suppl S):147S-161S.

11. **Werner CM, Steinmann PA, Gilbart M, Gerber C.** Treatment of painful pseudoparesis due to irreparable rotator cuff dysfunction with the Delta III reverse-ball-and-socket total shoulder prosthesis. *J Bone Joint Surg Am.* 2005; 87:1476-86.

12. **Roche C, Flurin PH, Wright T, Zuckerman JD.** Geometric Analysis of the Grammont Reverse Shoulder Prosthesis: an evaluation of the relationship between prosthetic design parameters and clinical failure modes. Proceedings of the 2006 ISTA Meeting. NY, NY. 2006.

13. **Roche C, Flurin PH, Wright T, Crosby LA, Mauldin M, Zuckerman JD.** An evaluation of the relationships between reverse shoulder design parameters and range of motion, impingement, and stability. *J Shoulder Elbow Surg.* 2009. Sep-Oct;18(5):734-41. doi: 10.1016/j.jse.2008.12.008.

14. **Roche C, Flurin PH, Wright T, Crosby LA, Jones, R, Mauldin M, Zuckerman JD.** Anterior and Posterior Scapular Impingement Associated with Two Reverse Shoulder Designs. Trans. of the 56th Annual ORS Meeting. 2010.

15. **Roche CP, Marczuk Y, Wright TW, Flurin PH, Grey SG, Jones RB, Routman HD, Gilot GJ, Zuckerman JD.** Scapular notching in reverse shoulder arthroplasty: validation of a computer impingement model. *Bull Hosp Jt Dis* (2013). 2013;71(4):278-83.

16. **Roche CP, Marczuk Y, Wright TW, Flurin PH, Grey S, Jones R, Routman HD, Gilot G, Zuckerman JD.** Scapular notching and osteophyte formation after reverse shoulder replacement: Radiological analysis of implant position in male and female patients. *Bone Joint J.* 2013 Apr;95-B(4):530-5. doi:10.1302/0301-620X.95B4.30442.

17. **Karelse AT, Bhatia DN, De Wilde LF.** Prosthetic component relationship of the reverse Delta III total shoulder prosthesis in the transverse plane of the body. *J Shoulder Elbow Surg.* 2008 Jul-Aug;17(4):602-7. doi: 10.1016/j.jse.2008.02.005.

18. **Kempton LB, Balasubramaniam M, Ankerson E, Wiater JM.** A radiographic analysis of the effects of glenosphere position on scapular notching following reverse total shoulder arthroplasty. *J Shoulder Elbow Surg.* 2011 Sep;20(6):968-74. doi:10.1016/j.jse.2010.11.026.

19. **Flatow EL, Harrison AK.** A history of reverse total shoulder arthroplasty. *Clin. Orthop. Relat. Res.* 2011 Sep;469(9):2432-2439. doi:10.1007/s11999-010-1733-6

20. **Grammont P, Trouilloud P, Laffay JP, Deries X.** Etude et réalisation d'une nouvelle prothèse d'épaule. Rhumatologie. 39(10):407-418.

21. **Boileau P, Melis B, Duperron D, Moineau G, Rumian AP, Han Y.** Revision surgery of reverse shoulder arthroplasty. *J Shoulder Elbow Surg.* 2013 Oct;22(10):1359-70. doi: 10.1016/j.jse.2013.02.004.

22. **Greene, A, Hamilton, M, Jacobson, A, Flurin, PH, Wright, T, Zuckerman, J, Roche, C.** Scapula Anatomy Study with Consideration to Reverse Shoulder Arthroplasty Biomechanics and Design. Trans. of the 60th Annual ORS Meeting. 2014.

23. **Nigro PT, Gutiérrez S, Frankle MA.** Improving glenoid-side load sharing in a virtual reverse shoulder arthroplasty model. *J Shoulder Elbow Surg.* 2013 Jul;22(7):954-62. doi: 10.1016/j.jse.2012.10.025.

24. **Hart ND, Clark JC, Wade Krause FR, Kissenberth MJ, Bragg WE, Hawkins RJ.** Glenoid screw position in the Encore Reverse Shoulder Prosthesis: an anatomic dissection study of screw relationship to surrounding structures. *J Shoulder Elbow Surg.* 2013 Jun;22(6):814-20. doi: 10.1016/j.jse.2012.08.013.

25. **Roche CP, Diep P, Hamilton MA, Flurin PH, Routman HD.** Comparison of bone removed with reverse total shoulder arthroplasty. *Bull Hosp Jt Dis* (2013). 2013;71 Suppl 2:S36-40.

26. ASTM 2028-14 Standard Test Methods for Dynamic Evaluation of Glenoid Loosening or Disassociation. West Conshohocken (PA): ASTM International; 2014.

27. **Roche C, Flurin PH, Wright T, Crosby LA, Hutchinson D, Zuckerman JD.** Effect of Varying Screw Configuration and Bone Density on Reverse Shoulder Glenoid Fixation following Cyclic Loading. Trans. of 54th Annual ORS Meeting, 2008.

28. **Roche C, Steffens, J, Flurin PH, Wright T, Crosby LA, Zuckerman JD.** Reverse Shoulder Glenoid Loosening Test Method: an analysis of fixation between two different offset glenospheres. Trans. of the 57th Annual ORS Meeting. 2011.

29. **Roche CP, Stroud NJ, Flurin PH, Wright TW, Zuckerman JD, Dipaola MJ.** Reverse Shoulder Glenoid Baseplate Fixation: a Comparison of Flat-Back vs Curve-Back Designs and Oval vs Round Designs with 2 Different Offset Glenospheres. *J Shoulder Elbow Surg.* 2014. In press.

30. **Stroud N, DiPaola MJ, Flurin PH, Roche CP.** Reverse shoulder glenoid loosening: an evaluation of the initial fixation associated with six different reverse shoulder designs. *Bull Hosp Jt Dis* (2013). 2013;71 Suppl 2:S12-7.

31. **Stroud NJ, DiPaola MJ, Martin BL, Steiler CA, Flurin PH, Wright TW, Zuckerman JD, Roche CP.** Initial glenoid fixation using two different reverse shoulder designs with an equivalent center of rotation in a low-density and high-density bone substitute. *J Shoulder Elbow Surg.* 2013 Nov; 22(11):1573-9. doi:10.1016/j.jse.2013.01.037.

32. **Roche CP, Stroud NJ, Martin BL, Steiler CA, Flurin PH, Wright TW, Zuckerman JD, Dipaola MJ.** Achieving fixation in glenoids with superior wear using reverse shoulder arthroplasty. *J Shoulder Elbow Surg.* 2013 Dec;22(12):1695-701. doi: 10.1016/j.jse.2013.03.008.

33. **Roche CP, Diep P, Grey SG, Flurin PH.** Biomechanical impact of posterior glenoid wear on anatomic total shoulder arthroplasty. *Bull Hosp Jt Dis* (2013). 2013;71 Suppl 2:S5-11.

34. **Roche C, Diep P, Hamilton M, Wright T, Flurin PH, Zuckerman J, Routman H.** Biomechanical Analysis of 3 Commercially Available Reverse Shoulder Designs in a Normal and Medially Eroded Scapula. Trans. of the 59th Annual ORS Meeting. 2013.

35. **Frankle M, Levy JC, Pupello D, Siegal S, Saleem A, Mighell M, Vasey M.** The reverse shoulder prosthesis for glenohumeral arthritis associated with severe rotator cuff deficiency. a minimum two-year follow-up study of sixty patients surgical technique. J *Bone Joint Surg Am.* 2006 Sep;88 Suppl 1 Pt 2:178-90.

36. **Hamilton MA, Roche CP, Diep P, Flurin PH, Routman HD.** Effect of prosthesis design on muscle length and moment arms in reverse total shoulder arthroplasty. *Bull Hosp Jt Dis* (2013). 2013;71 Suppl 2:S31-5.

37. **Hamilton M, Diep P, Roche C, Wright T, Flurin PH, Zuckerman J, Routman H.** The Effect of Reverse Shoulder Design on the Moment Arms of Muscles Surrounding the Joint During External Rotation. Trans. of the 59th Annual ORS Meeting. 2013.

38. **Hamilton M, Diep P, Roche C, Wright T, Flurin PH, Zuckerman J, Routman H.** How does reverse shoulder design affect rotator muscle moment arms? Transactions of the 8th Combined Meeting of the Orthopaedic Research Societies. 2013.

39. **Hamilton M, Diep P, Roche C, Wright T, Flurin PH, Zuckerman J, Routman H.** The effect of muscle wrapping on modeling of reverse shoulders. Transactions of the 8th Combined Meeting of the Orthopaedic Research Societies. 2013.

40. **Roche C and Crosby L.** Kinematics and Biomechanics of Reverse Total Shoulder Arthroplasty. Book Chapter. AAOS Orthopaedic Knowledge Update. #4: 45-54. 2013.

41. **Roche CP, Diep P, Hamilton M, Crosby LA, Flurin PH, Wright TW, Zuckerman JD, Routman HD.** Impact of inferior glenoid tilt, humeral retroversion, bone grafting, and design parameters on muscle length and deltoid wrapping in reverse shoulder arthroplasty. *Bull Hosp Jt Dis* (2013). 2013;71(4):284-93.

42. **Roche C, Diep P, Hamilton M, Wright T, Flurin PH, Zuckerman J, Routman H.** Asymmetric Tensioning of the Rotator Cuff by Changing Humeral Retroversion in Reverse Shoulder Arthroplasty. Trans. of the 59th Annual ORS Meeting. 2013.

43. **Roche CP, Hamilton MA, Diep P, Flurin PH, Routman HD.** Design rationale for a posterior/superior offset reverse shoulder prosthesis. *Bull Hosp Jt Dis* (2013). 2013;71 Suppl 2:S18-24.

44. **Flurin PH, Marczuk Y, Janout M, Wright TW, Zuckerman J, Roche CP.** Comparison of outcomes using anatomic and reverse total shoulder arthroplasty. *Bull Hosp Jt Dis* (2013). 2013;71 Suppl 2:101-7.

45. **Nolan BM, Ankerson E, Wiater JM.** Reverse total shoulder arthroplasty improves function in cuff tear arthropathy. *Clin Orthop Relat Res.* 2011 Sep;469(9):2476-82. doi: 10.1007/s11999-010-1683-z.

46. **Zumstein MA, Pinedo M, Old J, Boileau P.** Problems, complications, reoperations, and revisions in reverse total shoulder arthroplasty: a systematic review. *J Shoulder Elbow Surg.* 2011 Jan;20(1):146-57. doi:10.1016/j.jse.2010.08.001.

47. **Kontaxis A, Johnson GR.** The biomechanics of reverse anatomy shoulder replacement–a modelling study. *Clin Biomech* (Bristol, Avon). 2009 Mar;24(3):254-60.

48. **Terrier A, Reist A, Merlini F, Farron A.** Simulated joint and muscle forces in reversed and anatomic shoulder prostheses. *J Bone Joint Surg Br.* 2008 Jun;90(6):751-6. doi: 10.1302/0301-620X.90B6.19708.

49. **Crosby LA, Hamilton A, Twiss T.** Scapula fractures after reverse total shoulder arthroplasty: classification and treatment. *Clin Orthop Relat Res.* 2011 Sep;469(9):2544-9. doi: 10.1007/s11999-011-1881-3.

50. **De Wilde LF, Audenaert EA, Berghs BM.** Shoulder prostheses treating cuff tear arthropathy: a comparative biomechanical study. *J Orthop Res.* 2004 Nov;22(6):1222-30.

51. **Henninger HB, Barg A, Anderson AE, Bachus KN, Burks RT, Tashjian RZ.** Effect of lateral offset center of rotation in reverse total shoulder arthroplasty: a biomechanical study. *J Shoulder Elbow Surg.* 2012 Sep;21(9):1128-35. doi: 10.1016/j.jse.2011.07.034.

52. **Levy JC, Anderson C, Samson A.** Classification of postoperative acromial fractures following reverse shoulder arthroplasty. *J Bone Joint Surg Am.* 2013 Aug 7;95(15):e104. doi: 10.2106/JBJS.K.01516.

53. **Crosby L and Wright, T.** Revision Total Shoulder Arthroplasty with and without Humeral Stem Removal: How Much of a Difference Does it Make in the Overall Results? Trans of the 23rd Annual BESS Scientific Meeting. 2012.

EVALUATION OF THE ACCURACY AND PRECISION OF A NEXT GENERATION COMPUTER-ASSISTED SURGICAL SYSTEM

Laurent D. Angibaud, BS
Exactech, Inc.

Yifei Dai, PhD
Exactech, Inc.

Ralph A. Liebelt, MD
North Carolina Specialty Hospital

Bo Gao, PhD
Exactech, Inc.

Scott W. Gulbransen
Exactech, Inc.

Xeve S. Silver, BS
Exactech, Inc.

www.exac.com/courses
June 13 | Advanced Surgical Solutions for Total Hip and Knee Arthroplasty **| Las Vegas, NV**

INTRODUCTION

The long-term clinical success of the total knee arthroplasty (TKA) is critically dependent on the accurate positioning of the prosthesis.[1-3] Studies have shown that malalignment can lead to various complications, such as component loosening and instability, polyethylene wear, and patellar dislocation.[4-6] In the coronal plane, greater than 3° varus/valgus postoperative knee alignment has been found to increase the risk of negative outcomes,[4,5] with mechanisms of failure generally being medial collapse for the varus malaligned knees, and ligament instability for the valgus malaligned knees.[7,8] In the sagittal plane, malalignment of the components has been linked to an increased failure rate (3.3 percent and 4.5 percent for femur and tibia, respectively) compared to neutrally aligned components (0 percent and 0.2 percent for femur and tibia, respectively).[9] Although numerous studies have stressed the importance of ensuring accurate component position and orientation, TKA performed using conventional instruments still largely relies on the surgeon's experience and skill level to achieve this goal. It has been reported that conventional implantation techniques involving the use of extramedullary or intramedullary mechanical instruments can only achieve satisfactory lower limb alignment (within ± 3° of varus/valgus relative to mechanical axis) in 60 to 80 percent of the cases.[5,10,11] Another notable fact is that arthroplasty registry data indicates 20 to 25 percent of patients remain dissatisfied with the results of the surgery,[12-14] which may partially be attributed to component malalignment.[15]

Computer-assisted orthopaedic surgery (CAOS) has been shown to offer more accurate, reliable and reproducible component positioning compared to conventional techniques.[16-19] In a 2008 cohort study, CAOS was found to provide both closer restoration to the neutral mechanical alignment and approximately double the cases of optimal alignment compared to the conventional instrumentation group.[17] Sparmann et al.[18] reported only 2 percent of outliers (> 3° in varus/valgus alignment) in the TKA cases

A

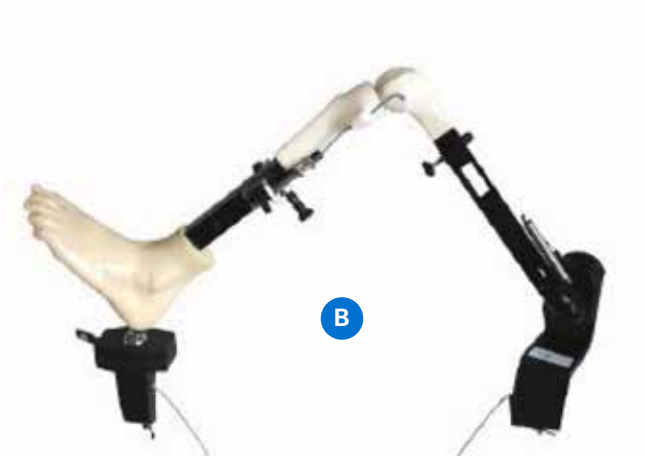

B

C

Figure 1. A) A typical set up for the ExactechGPS system inside the sterile field. B) A whole leg assembly used for this study. C) A representative knee insert with anatomical landmarks identified using the metal probe. FDC: femur distal center, FDM: femur medial distal condyle, FDL: femur lateral distal condyle, FPM: femur medial posterior condyle, TPC: tibia proximal center, FPL: femur lateral posterior condyle, TPM: tibia lowest point on the medial peateau, TPL: tibia lowest point on the lateral plateau.

using an imageless CAOS system (ExactechGPS®, Blue-Ortho, Grenoble, France), compared to 22 percent of the conventional instrumentation cases. Also, the differences between the CAOS system and conventional alignment method were found to be significant in both coronal and sagittal planes.

Similar conclusions were drawn in many other studies.[16,19] However, despite the fact that CAOS has demonstrated its advantage over conventional instrumentation in terms of implant positioning, wide application of this technology turned out to be challenging due to several limitations, including cost for the system, increased operating time and bulky equipment. Furthermore, the intraoperative use of such systems can be cumbersome due to equipment placed out of the surgical field, causing difficulties in user-system interaction. Furthermore, the optical markers in many tracker designs are prone to be easily blocked from the view of the camera by surgical staff and bloody fluid.

Recent advances in computer and optical technologies enabled the development of a next generation imageless CAOS system, which provides the solutions to multiple limitations of the traditional CAOS systems. Specifically, ExactechGPS allows the integrated camera and display unit to be located within the sterile field, providing maximum accessibility by the surgeon (Figure 1A). The wireless active trackers are resistant to blood occlusion, ensuring optimum visualization by the optical camera. Also, the system enables the surgeon to easily customize individual preference in operative technique, instruments used and surgical workflow, such that the surgery can be performed following the procedure he/she is trained and most comfortable with. Finally, patient-specific TKA resections are enabled by the real-time guidance provided by the system in combination with the smart instrumentation, based on individual patient's anatomy.

The introduction of such next generation CAOS system requires an understanding of its accuracy and precision,

Table 1. Anatomical Landmarks Identified by Metal Probe and Unigraphics

Landmark	Abbreviation	Landmark	Abbreviation
Femur (by metal probe)		**Tibia (by metal probe)**	
Medial posterior condyle	FP_M	Lowest point on the medial peateau	TP_M
Lateral posterior condyle	FP_L	Lowest point on the lateral plateau	TP_L
Medial distal condyle	FD_M	Proximal center	TP_C
Lateral distal condyle	FD_L	**Tibia (definied in Unigraphics)**	
Distal center	FD_C	Ankle center	TA_C
Femur (defined in Unigraphics)			
Head center	FH_C		

Table 2. Definition of the Reference Axes and Anatomical Planes for Total Knee Arthroplasty Resections

Landmark	Abbreviation	Definition
Femur		
Mechanical axis	FMA	Line connecting FH_C and FD_C
Posterior condyle line	FPCL	Line connecting FP_M and FP_L
Coronal plane	FCP	Plane parallel to both FMA and FPCL
Sagittal plane	FSP	Plane perpendicular to FCP and parallel to FMA
Tibia		
Mechanical axis	TMA	Line connecting TP_C and TA_C
Coronal plane	TCP	Plan perpendicular to TSP and parallel to TMA
Sagittal plane	TSP	Plane passing through TMA and oriented to the second toe

FH_C: femur head center, FD_C: femur distal center, FP_M: femur medial posterior condyle, FP_L: femur lateral posterior condyle, TP_C: tibia proximal center, TA_C: tibia ankle center.

which can be dictated both in system level (hardware and software) and clinical alignment outcomes. Previous evaluations of CAOS systems for TKA have been mostly focused on the final implant position and alignment in the reconstructed knee joint.[17-19] The intrinsic accuracy of the systems themselves has generally been overlooked. However, recent development in the CAOS related research pointed out that significant differences may exist across different CAOS systems in both coronal alignment and the number of radiographic outliers,[20] and concluded that surgeons should not consider all the TKA CAOS systems to be equally accurate. This finding addressed the importance to evaluate the system accuracy for individual CAOS system to understand the errors generated by the hardware system and software algorithm on the surgical resection level. The purpose of this study was therefore to evaluate the accuracy and precision of the intraoperative surgical resection measurements performed by the ExactechGPS system under the lab setting, and assesses the impact of extra-articular knee deformity on measurement errors.

METHODS

Specimen Preparation

Twenty-eight synthetic knee inserts (MITA knee insert, Medical Models, Bristol, UK) were used in this study, including 12 neutral knees (Catalog no. M-00598), 12 varus knees (5° of deformity, Catalog no. M-00566), and four valgus knees (12° of deformity, Catalog no. M-00567). An artificial leg (MITA trainer leg, Catalog no. M-00058, Medial Models) was used to assemble with each insert to simulate the entire leg (Figure 1B).

At the beginning of the study, a set of anatomical landmarks were annotated by firmly pressing a metal probe into the surface of the knee inserts to create small dimples with the same diameter as the tip of the ExactechGPS probe tracker (Figure 1C). The landmarks acquired in this step and their abbreviations are listed in Table 1. Next, the knee inserts and the artificial leg were digitized individually using a three-dimensional (3D) scanner (Comet L3D, Steinbichler, Plymouth, MI, USA). The

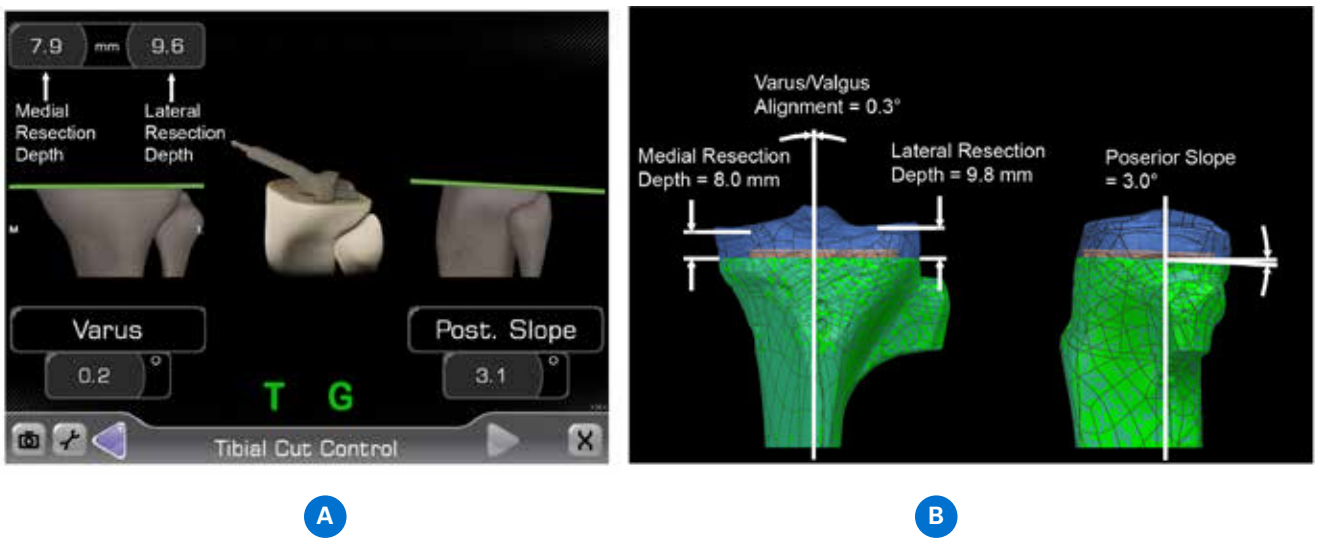

Figure 2. Measurements of resection depths and alignment angles on the same representative tibia by ExactechGPS CAOS system A) and using three-dimensional scan-based surface registration B). CAOS: computerassisted orthopaedic surgery, T: The CAOS system is referencing the Tibial Tracker in this step, G: The CAOS system is referencing the Guide Tracker in this step.

digitized surfaces were then created (Verify64 and DesignX 64 , Geomagic, Lakewood, CO, USA). Under the CAD environment (Unigraphics NX ver. 7.5, Siemens PLM Software, Plano, TX, USA), each insert was virtually assembled with the artificial leg to create a whole leg assembly. The preannotated surface landmarks were recreated on the knee inserts in Unigraphics by identifying the center of each surface dimple. Two additional landmarks were defined in Unigraphics (Table 1): (1) femoral head center (FHC): the center of the fitted sphere of the femoral head on the artificial leg; and (2) ankle joint center (TAC): the midpoint between medial and lateral malleoli, which were annotated on the surface of the ankle. Based on the landmarks, a set of anatomical axes and planes were established for each whole leg assembly in Unigraphics, serving as the reference for TKA resections. The detailed definition of the reference system is described in Table 2.

Computer-assisted TKA Resection

Computer-assisted TKA resections were performed by a board-certified orthopaedic surgeon (RAL) using ExactechGPS guidance system on each physical whole leg assembly. The knees were prepared targeting following the Optetrak Logic® PS knee implants operative technique (Exactech, Gainesville, FL, USA). First, a surgeon profile was set up in the CAOS guidance system according to the surgeon's preference on the philosophy, surgical flow and instrumentation. Second, the probe tracker was used during the CAOS procedure to acquire the same set of anatomical landmarks by probing the precreated dimples on the surfaces of the whole leg assembly (Table 1), except for FHC, which was identified by the guidance system following the "rotational method."[21] The cutting blocks were then fixed onto the femur and tibia, adjusted individually to the desired resection parameters, and used to guide the saw blade for bone resections. The resections aimed for the restoration of the mechanical axis and accurate rotational alignment of the knee components. For this specific study, only the first resection on each bone type was made, namely, the distal resection of the femur and the proximal resection for the tibia.

The final surgical parameters were collected intraoperatively by the CAOS guidance system after the resections (intraoperatively measured surgical parameters) (Figure 2A). The data recorded included the medial and lateral tibial resection depths, tibial varus/

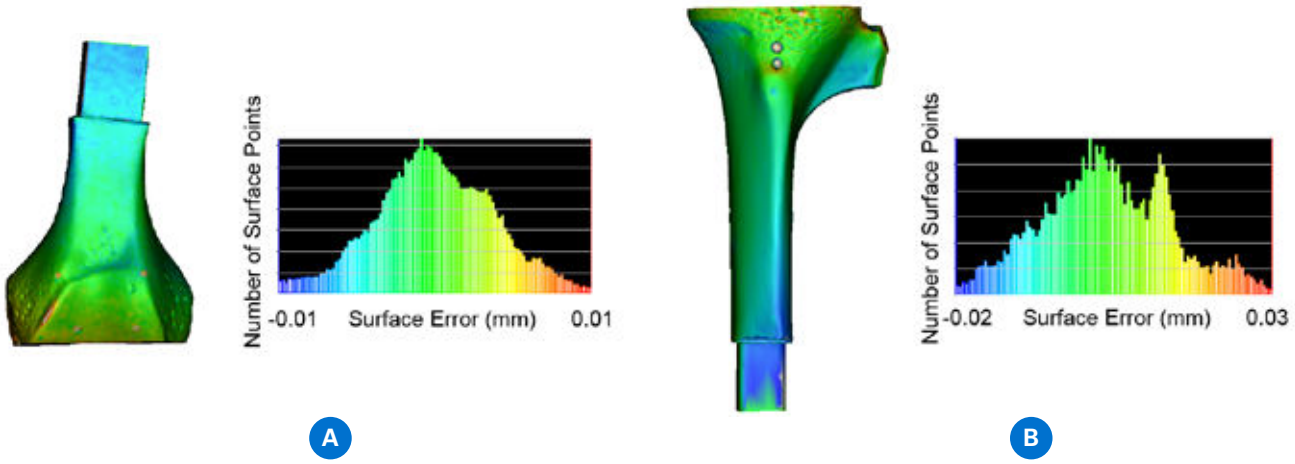

Figure 3. Representative tibia A) and femur B) demonstrating surface error (plotted on the resected bones) between registered preoperative and postoperative three-dimensional scanned surfaces. Distribution of the surface error is also shown for each bone.

valgus alignment, tibial posterior slope, medial and lateral distal femoral resection depths, femoral varus/valgus alignment, and femoral flexion/extension angle. The measurement algorithms for the surgical parameters are summarized below: (1) Medial and lateral tibial resection depths: the perpendicular distances from tibia lowest point on the medial peateau (TPM) and tibia lowest point on the lateral plateau (TPL) to the tibial resection plane, respectively. (2) Tibial varus/valgus alignment: the angle between tibia mechanical axis (TMA) and the normal of the tibial resection plane, projected onto the tibia coronal plane (TCP). (3) Tibial posterior slope: the angle between TMA and the normal of the tibial resection plane, projected onto the tibia sagittal plane (TSP). (4) Medial and lateral distal femoral resection depths: the perpendicular distances from FPM and FPL to the distal femoral resection plane, respectively. (5) Femoral varus/valgus alignment: the angle between femur mechanical axis (FMA) and the normal of the distal femoral resection plane, projected onto the femur coronal plane. (6) Femoral flexion/extension angle: the angle between FMA and the normal of the distal femoral resection plane, projected onto the femur sagittal plane (FSP).

Postoperative Measurement

Following the TKA resections, 3D scans were repeated on each knee insert. The digitized postresection bone surfaces were registered with the corresponding whole bone surfaces. In Unigraphics, 3D model of the instrument used for intraoperative bone resection check was virtually placed on each resected tibia and femur. Surgical resection planes were recreated from the bone-contacting plane of the checker instrument. The same set of surgical resection parameters (actual surgical parameters) were measured in the predefined anatomical referencing system using Geomagic software platform (Figure 2B). To assess the accuracy of the surface registration workflow, one tibia and one femur were selected from each deformity groups (neutral, varus, and valus). The surface distance error between each registered preoperative and postoperative bone surface pair was computed (3-matic 8.0, Materialise, Leuven, Belgium) and averaged across the six sampled bones. Both the mean surface distance (0.0007mm) and its associated standard deviation (SD, 0.0037mm) were found to be lower than the level of accuracy reported in this study (0.01mm) (Figure 3). The workflow was therefore confirmed to be sufficiently accurate.

Table 3. Unassigned Errors of the ExactechGPS System on Surgical Resection Parameter Measurements

Bone	Parameter	Varus	Neutral	Valgus	Deformed (varus + valgus)	Pooled
Tibia	Medial Resection Depth (mm)	0.35 ± 0.38	0.46 ± 0.29	0.40 ± 0.21	0.37 ± 0.34	0.41 ± 0.32
	Lateral Resection Depth (mm)	0.55 ± 0.63	0.38 ± 0.27	0.38 ± 0.38	0.51 ± 0.57	0.46 ± 0.46
	Varus/Valgus Alignment (°)	0.49 ± 0.35	0.54 ± 0.35	0.25 ± 0.14	0.43 ± 0.33	0.48 ± 0.33
	Posterior Slope (°)	0.41 ± 0.29	0.90 ± 0.35	0.37 ± 0.21	0.40 ± 0.27	0.62 ± 0.39
	Error Index [95 percent Confidence Interval]	0.45 ± 0.27 [0.28, 0.62]	0.57 ± 0.11 [0.50, 0.64]	0.35 ± 0.17 [0.08, 0.63]	0.43 ± 0.39 [0.22, 0.64]	0.49 ± 0.19 [0.42, 0.56]
Femur	Medial Resection Depth (mm)	0.41 ± 0.21	0.34 ± 0.24	0.32 ± 0.38	0.38 ± 0.25	0.36 ± 0.24
	Lateral Resection Depth (mm)	0.53 ± 0.37	0.68 ± 0.46	0.63 ± 0.35	0.56 ± 0.36	0.61 ± 0.40
	Varus/Valgus Alignment (°)	0.25 ± 0.15	0.44 ± 0.32	0.22 ± 0.11	0.24 ± 0.14	0.33 ± 0.25
	Flexion/Extension Angle (°)	0.54 ± 0.41	0.68 ± 0.52	0.80 ± 0.55	0.60 ± 0.45	0.64 ± 0.47
	Error Index [95 percent Confidence Interval]	0.43 ± 0.13 [0.35, 0.52]	0.54 ± 0.23 [0.39, 0.68]	0.49 ± 0.19 [0.21, 0.78]	0.45 ± 0.34 [0.27, 0.63]	0.49 ± 0.15 [0.43, 0.55]

Values are presented as mean ± standard deviation.

Table 4. Signed Errors of the ExactechGPS System on Surgical Resection Parameter Measurements

Bone	Parameter	Varus	Neutral	Valgus	Deformed (varus + valgus)	Pooled
Tibia	Medial Resection Depth (mm)	0.10 ± 0.52 [-0.23, 0.43]	0.46 ± 0.29 [0.28, 0.64]	-0.33 ± 0.34 [-0.87, 0.21]	-0.01 ± 0.51 [-0.28, 0.26]	0.19 ± 0.48 [0.00, 0.38]
	Lateral Resection Depth (mm)	-0.35 ± 0.77 [-0.84, 0.14]	0.23 ± 0.42 [-0.03, 0.50]	-0.32 ± 0.45 [-1.04, 0.40]	-0.34 ± 0.69 [-0.71, 0.03]	-0.10 ± 0.65 [-0.35, 0.15]
	Varus/Valgus Alignment (°)	0.05 ± 0.62 [-0.35, 0.44]	-0.25 ± 0.61 [-0.64, 0.14]	0.05 ± 0.32 [-0.46, 0.56]	0.05 ± 0.55 [-0.24, 0.34]	-0.08 ± 0.58 [-0.31, 0.15]
	Posterior Slope (°)	-0.07 ± 0.51 [-0.40, 0.25]	0.90 ± 0.35 [0.68, 1.12]	0.37 ± 0.21 [0.02, 0.71]	0.04 ± 0.49 [-0.22, 0.30]	0.41 ± 0.61 [0.17, 0.65]
Femur	Medial Resection Depth (mm)	-0.13 ± 0.45 [-0.42, 0.16]	-0.04 ± 0.42 [-0.31, 0.23]	-0.13 ± 0.50 [-0.93, 0.67]	-0.13 ± 0.50 [-0.40, 0.14]	-0.09 ± 0.43 [-0.26, 0.08]
	Lateral Resection Depth (mm)	-0.49 ± 0.43 [-0.77, 0.22]	-0.49 ± 0.67 [-0.92, 0.07]	-0.42 ± 0.64 [-1.44, 0.59]	-0.42 ± 0.64 [-0.76, -0.08]	-0.48 ± 0.55 [-0.69 -0.27]
	Varus/Valgus Alignment (°)	-0.07 ± 0.29 [-0.26, 0.11]	-0.41 ± 0.37 [-0.64, 0.17]	-0.07 ± 0.27 [-0.50, 0.35]	-0.07 ± 0.27 [-0.21, 0.07]	-0.22 ± 0.36 [-0.36, 0.08]
	Flexion/Extension Angle (°)	0.23 ± 0.66 [-0.19, 0.65]	0.15 ± 0.87 [-0.40, 0.70]	0.80 ± 0.55 [-0.08, 1.67]	0.80 ± 0.55 [0.51, 1.09]	0.28 ± 0.75 [-0.01, 0.57]

Values are presented as mean ± standard deviation (95 percent confidence interval).
*Positive error indicates that compared to the actual surgical parameters, the intraoperative measured parameters had: (1) less bone resection depth, more varus alignment, and decreased posterior slope in the tibia and (2) less bone resection depth, more varus alignment, and less extension in the femur.

Data Analysis

The unsigned and signed differences between the actual surgical parameters and intraoperatively measured surgical parameters were calculated. The unsigned differences represent the magnitude of error generated in the measurements performed by the CAOS guidance system. The signed differences however, identify any bias of the measurement error, such as a tendency of resecting towards varus (or valgus), flexion (or extension), more (or less) resection depth, or an increased (or reduced) posterior slope in the alignment. The accuracy (mean error) and precision (SD) of the CAOS guidance system on each surgical resection parameter were measured (for both the signed and unsigned difference). The 95 percent confidence interval (CI) was assessed for the signed differences for each resection parameter by a single sample Student t-test (Minitab, Minitab Inc., State College, PA, USA). A unitless error index was introduced as the overall indication of the error magnitude within a specific group of interest. It was calculated as the mean and SD of the unsigned errors combining all the dimensional and angular measurements within a specific bone type/deformity group. This definition deemed a difference of 1mm and 1° in the surgical resections as of equivalent significance, as they are both at the same level of clinical detectability. The impact of preoperative knee condition on the accuracy and precision of the CAOS guidance system was investigated by comparing across the deformity groups. Statistical significance was defined as $P < 0.05$ (analysis of variance).

RESULTS

A summary of unsigned errors and error indexes can be found in Table 3. The data showed that minimum errors (≤ 0.68 mm for resection depths, ≤ 0.90° for angular measurements) were generated by the CAOS guidance system across all the deformity groups (neutral, varus, valgus, and deformed in general) and bone types (femur and tibia). The pooled mean errors were equal or less than 0.61mm and 0.64° for resection depths and angular measurements, respectively. Regardless of bone type and deformity group, both the mean and SD of the error Indexes were small and clinically undetectable (means ≤ 0.57, SDs ≤ 0.39). No statistical difference was found in error index between tibia and femur, nor between the knee deformity groups. Regardless of the nature of the knee deformity, the mean signed error of the CAOS guidance system was systematically less than 0.5mm for bone resection depths, and equal or less than 0.9° for joint angle measurements (Table 4), with pooled means less than 0.5mm and 0.5°, respectively. The guidance system was shown to have a slight tendency to measure more in distal femoral resection depth and increased femoral valgus compared to the actual resection (negative values in the mean errors). However, the biases were not clinically meaningful (< 0.50mm in resection depths, < 0.50° in varus/valgus alignment measurements). No other biases were found in the rest of the surgical resection parameters. The 95 percent CIs were in the ranges of –1.44 to 0.67mm for bone resection depths, and –0.64° to 1.67° for angular measurements. The differences across bone types and deformity groups were not found to be statistically significant.

The results of this study demonstrated that the ExactechGPS system can offer intraoperative imageless surgical assistance with both high accuracy and precision.

DISCUSSION

Accurate TKA bone resection is crucially important for the accurate placement of the component. In the TKA cases using conventional mechanical alignment guides, achieving proper bony resection depends on the design and accuracy of the instruments, surgical assumptions such as valgus alignment adjustment from the mechanical axis, as well as the experience and skill level of thesurgeon. None of these factors can be free of error, nor is quantitative real-time feedback available during the procedure. Clinical studies have reported outliers in postoperative limb alignment to be ranged from 26 to 28 percent in the conventional group, compared to 0 to 3 percent in the navigation group.[16,18,19] The results of this study demonstrated that the ExactechGPS system can offer intraoperative imageless surgical assistance with both high accuracy and precision. The contribution of the system itself to the total surgical variability was shown to be clinically negligible (sub-millimeter for resection depth, and sub-degree for alignment). Also, the system does not significantly bias the measurements, providing highly reliable feedbacks during the surgical operation. Furthermore, the results showed that ExactechGPS consistently provides accurate and precise measurements regardless of the status of preoperative extra-articular knee deformity (neutral, varus, or valgus).

Intraoperative measurement of surgical resection parameters during imageless computer-assisted TKA surgery is a critical step, in which a surgeon directly relies on the real-time data obtained by the optical trackers to prepare the bony resections and check the final realized cuts. As pointed out by a previous study,[22] computer assisted surgical systems provides a "smart" user interface at the surgical application level, which tends to cause the overlooking of the underlying hardware setup and software algorithm during the assessment of CAOS systems. As the result, numerous studies have investigated the impact of landmarking and overall clinical accuracy of the computer-assisted surgical in knee arthroplasty,[17-19,23,24] yet limited information is available on the error caused by the CAOS systems themselves during the intraoperative measurement of surgical resection parameters. In a 2004 study, Wiles et al.[22] quantified the accuracy of an optical tracking system by assessing the distance error between position measurements performed by the system and the benchmark locations. Although the study provided great contribution to the methodology for assessing the accuracy of such systems, interpolation of the reported singlemarker and rigid body based errors to clinical meaningful surgical resection parameters may be challenging. Another published investigation assessed the accuracy of an imageless navigation system by comparing measured alignment data between an imageless CAOS system and a digital caliper for various knee deformity types. However, the manual probing process may be subjected to human error, and only alignment angles were studied. This present study reported comparable or higher level of accuracy for the ExactechGPS system for the angular measurements with additional accuracy assessment on the surgical resection depths.

This study presented a set of methodology and workflow to assess the system-level accuracy of CAOS systems. The use of 3D scanned data provided a high resolution, non-contact method that eliminated errors associated with users or movement during data acquisition compared to using a digital caliper unit. Furthermore, anatomical landmarks were annotated and preserved on both pre- and postoperative knees, which ensures the anatomical based surgical referencing system to be consistent throughout the assessment for accurate registration and measurement of the bone resections. Both advantages offer improved accuracy of the measurement workflow. Especially given the small magnitude of the reported errors, errors from data acquisition and processing in this study were kept to a minimum. One limitation of the study was that it was performed *in vitro*. Since the error was calculated between the intraoperative measured and actual resection parameters on the finished bony cut, lack of soft tissue environment was not expected to affect the data. However, the impact of other factors in the operating room setting (e.g., blood occlusion, presence of surgical staff and other surgical equipment in the camera field) on the results may be further investigated.

In conclusion, this study demonstrated that the ExactechGPS system can offer both accurate and precise imageless intraoperative surgical resection measurements during computer-assisted TKA, regardless of the deformity status of the knees. The errors generated by this CAOS guidance system were clinically negligible. •

Copyright © 2015 by The Korean Orthopaedic Association. Reprinted under the Creative Commons Atribution Non-commercial Liscense from Clinics in Orthopedic Surgery • Vol. 7, No. 2, 2015.

REFERENCES

1. **Fehring TK, Odum S, Griffin WL, Mason JB, Nadaud M.** Early failures in total knee arthroplasty. *Clin Orthop Relat Res.* 2001;(392):315-8.

2. **Schroer WC, Berend KR, Lombardi AV, et al.** Why are total knees failing today? Etiology of total knee revision in 2010 and 2011. *J Arthroplasty.* 2013;28(8 Suppl):116-9.

3. **Sharkey PF, Hozack WJ, Rothman RH, Shastri S, Jacoby SM.** Insall Award paper: why are total knee arthroplasties failing today? *Clin Orthop Relat Res.* 2002;(404):7-13.

4. **Jeffery RS, Morris RW, Denham RA.** Coronal alignment after total knee replacement. *J Bone Joint Surg Br.* 1991;73(5):709-14.

5. **Ritter MA, Faris PM, Keating EM, Meding JB.** Postoperative alignment of total knee replacement: its effect on survival. *Clin Orthop Relat Res.* 1994;(299):153-6.

6. **Wasielewski RC, Galante JO, Leighty RM, Natarajan RN, Rosenberg AG.** Wear patterns on retrieved polyethylene tibial inserts and their relationship to technical considerations during total knee arthroplasty. *Clin Orthop Relat Re*s. 1994;(299):31-43.

7. **Berend ME, Ritter MA, Meding JB, et al.** Tibial component failure mechanisms in total knee arthroplasty. *Clin Orthop Relat Res.* 2004;(428):26-34.

8. **Fang DM, Ritter MA, Davis KE.** Coronal alignment in total knee arthroplasty: just how important is it? *J Arthroplasty.* 2009;24(6 Suppl):39-43.

9. **Kim YH, Park JW, Kim JS, Park SD.** The relationship between the survival of total knee arthroplasty and postoperative coronal, sagittal and rotational alignment of knee prosthesis. *Int Orthop.* 2014;38(2):379-85.

10. **Ensini A, Catani F, Leardini A, Romagnoli M, Giannini S.** Alignments and clinical results in conventional and navigated total knee arthroplasty. *Clin Orthop Relat Res.* 2007;457:156-62.

11. **Parratte S, Pagnano MW, Trousdale RT, Berry DJ.** Effect of postoperative mechanical axis alignment on the fifteen-year survival of modern, cemented total knee replacements. *J Bone Joint Surg Am.* 2010;92(12):2143-9.

12. **Baker PN, van der Meulen JH, Lewsey J, Gregg PJ**; National Joint Registry for England and Wales. The role of pain and function in determining patient satisfaction after total knee replacement: data from the National Joint Registry for England and Wales. *J Bone Joint Surg Br.* 2007;89(7):893-900.

13. **Bourne RB, Chesworth BM, Davis AM, Mahomed NN, Charron KD.** Patient satisfaction after total knee arthroplasty: who is satisfied and who is not? *Clin Orthop Relat Res.* 2010;468(1):57-63.

14. **Rothwell AG, Hooper GJ, Hobbs A, Frampton CM.** An analysis of the Oxford hip and knee scores and their relationship to early joint revision in the New Zealand Joint Registry. *J Bone Joint Surg* Br. 2010;92(3):413-8.

15. **Matsuda S, Kawahara S, Okazaki K, Tashiro Y, Iwamoto Y.** Postoperative alignment and ROM affect patient satisfaction after TKA. *Clin Orthop Relat Res.* 2013;471(1):127-33.

16. **Jenny JY, Clemens U, Kohler S, Kiefer H, Konermann W, Miehlke RK.** Consistency of implantation of a total knee arthroplasty with a non-image-based navigation system: a case-control study of 235 cases compared with 235 conventionally implanted prostheses. *J Arthroplasty.* 2005;20(7):832-9.

17. **Rosenberger RE, Hoser C, Quirbach S, Attal R, Hennerbichler A, Fink C.** Improved accuracy of component alignment with the implementation of image-free navigation in total knee arthroplasty. *Knee Surg Sports Traumatol Arthrosc.* 2008;16(3):249-57.

18. **Sparmann M, Wolke B, Czupalla H, Banzer D, Zink A.** Positioning of total knee arthroplasty with and without navigation support: a prospective, randomised study. *J Bone Joint Surg Br.* 2003;85(6):830-5.

19. **Zhang GQ, Chen JY, Chai W, Liu M, Wang Y.** Comparison between computer-assisted-navigation and conventional total knee arthroplasties in patients undergoing simultaneous bilateral procedures: a randomized clinical trial. *J Bone Joint Surg Am.* 2011;93(13):1190-6.

20. **Carli A, Aoude A, Reuven A, Matache B, Antoniou J, Zukor DJ.** Inconsistencies between navigation data and radiographs in total knee arthroplasty are system-dependent and affect coronal alignment. *Can J Surg.* 2014;57(5):305-13.

21. **Marin F, Mannel H, Claes L, Durselen L.** Accurate determination of a joint rotation center based on the minimal amplitude point method. *Comput Aided Surg.* 2003;8(1):30-4.

22. **Wiles AD, Thompson DG, Frantz DD.** Accuracy assessment and interpretation for optical tracking systems. *Proc SPIE.* 2004;5367:421-32.

23. **Hernandez-Vaquero D, Suarez-Vazquez A, Sandoval-Garcia MA, Noriega-Fernandez A.** Computer assistance increases precision of component placement in total knee arthroplasty with articular deformity. *Clin Orthop Relat Res.* 2010;468(5):1237-41.

24. **Lustig S, Fleury C, Servien E, Demey G, Neyret P, Donell ST.** The effect of pelvic movement on the accuracy of hip centre location acquired using an imageless navigation system. *Int Orthop.* 2011;35(11):1605-10.

THE EFFECT OF TAPER ANGLE AND SPLINE GEOMETRY ON THE INITIAL STABILITY OF TAPERED, SPLINED MODULAR TITANIUM STEMS

Jeffery L. Pierson, MD
Joint Replacement Surgeons of Indiana Foundation, Inc.

Scott R. Small, MS
Joint Replacement Surgeons of Indiana Foundation, Inc.

Jose A. Rodriguez. MD
Lenox Hill Hospital

Michael N. Kang, MD
Insall-Scott-Kelly Institute for Orthopaedics and Sports Medicine

Andrew H. Glassman, MD
The Ohio State University

www.exac.com/courses
April 8-9 | Advanced Surgical Solutions for Shoulder, Hip and Knee Arthroplasty **| Washington, DC**

There have been significant advances in revision total hip arthroplasty (THA) over the past two decades. In femoral revision surgery, tapered, splined modular titanium stems (TSMTSs) have emerged as a particularly effective option. In short to midtern follow-up, TSMTSs have reported minimum five-year survivorship of 85-94 percent[1-5] and have exhibited improved quality of life measures, fewer intraoperative fractures, and better ability to reproduce leg length and offset.[5-13]

While these results are encouraging, component subsidence continues to be a cause for early mechanical failure and a cause for re-revision (with increased subsidence associated with severity of bone defect).[5] Bohm and Bischel[14] reported an average migration of 5.9mm in 149 TSMTSs at a mean 4.8 year follow-up, with 26 hips exhibiting more than 10mm of migration. Rodriguez et al.[15] reported a 6.2 percent rate of subsidence up to 10mm at 6.2 years follow-up, while Park et al.[5] reported 5 percent of cases with 10-20mm of subsidence at 1.6 years. In many of these cases, secondary stability was reported without re-revision, attributed to the tapered design of the stem. Interestingly, the design rationale for the degree of taper angle and spline geometry is not well documented in the literature.

The purpose of this study was to evaluate the effect of two major design elements of a TSMTS (the degree of taper angle and spline geometry design) on the initial mechanical stability of the implant, as measured by implant subsidence and torsional resistance.

MATERIALS AND METHODS

In order to perform a comparative analysis of axial and torsional stability of revision stem spline designs, custom stem samples were manufactured from wrought titanium (Ti-6Al-4V) per ASTM Standard F1472-08. Experimental groups consisted of two spline configurations (Narrow and Broad) with five taper angle groups per spline configuration (2.5°, 3.0°, 3.5°, 4.0°, 5.0°), for a total of 10 distinct sample experimental groups. Three specimens were included in each spline configuration and taper angle combination group. All test specimens consisted of a 102mm of tapered spline, 18mm in



Figure 1. Mechanical drawings and three dimensional views of broad and narrow spline geometries showing taper angle and spline geometries as variables of interest in this study.

proximal diameter, with an additional 38mm smooth cylindrical stub 13mm in diameter to integrate with the test fixture. Stems included 10 longitudinal splines spaced circumferentially at an increment of 36°.The spline geometry in the narrow configuration had a 0.4-0.5mm wide spline, whereas the broad configuration had a 0.9-1.0mm wide spline. These spline widths were chosen as they reflected the range of spline widths observed in stems that are currently on the market and available for inspection. Both configurations had a spline height of 1.9mm (Figure 1). Solid rigid polyurethane foam blocks (0.64 g/cc, Sawbones, Inc., Vashon, WA) of size 50mm x 50mm x 20mm were used as the test substrate and were reamed utilizing standard manufacturer-supplied reamers, matching stem taper angles, on a digitized mill. Roughing, followed by finishing passes were performed to a diameter at which the center 20mm of the test specimen was engaged into the foam block.

Axial and torsional mechanical testing was conducted utilizing a biaxial electrodynamic load frame (ElectroPuls E10,000 A/T, Instron, Norwood, MA). Proximally, specimens were gripped in the upper pneumatic grip of the load frame. Distally, reamed foam specimens were placed within a hollow support chamber enabling stem insertion and rotation, while allowing for free x-y translation and constraining foam rotation. Axial tests were performed by inserting the test specimen at a displacement controlled rate of 1mm/s until a maximum specimen displacement of 15mm was reached. Maximum compressive load was calculated from the axial output of the load frame. Axial resistance was calculated utilizing a data analysis package (LoggerPro 3.8.5, Vernier Software & Technology, Beaverton, OR) as the slope of the linear region of the displacement-force curve in each trial. Specimens were cleaned and inspected for damage after each trial, with tests repeated five times per specimen in a new foam block for each trial.

The purpose of this study was to evaluate the effect of two major design elements of a TSMTS (the degree of taper angle and spline geometry design) on the initial mechanical stability of the implant, as measured by implant subsidence and torsional resistance.

Following axial testing, torsional resistance was quantified for each spline configuration and taper angle using the same experimental fixturing. Preliminary testing of axial insertion forces incrementally from 0 to 1000 N revealed an axial force of 400 N as the minimum threshold for spline penetration into the surface of the reamed foam. For this reason, a constant compressive axial preload of 400 N was ap plied to the stem specimen during all torsional tests as means to simulate slight cortical bone engagement at the onset of torque application. Each stem specimen was rotated within the foam

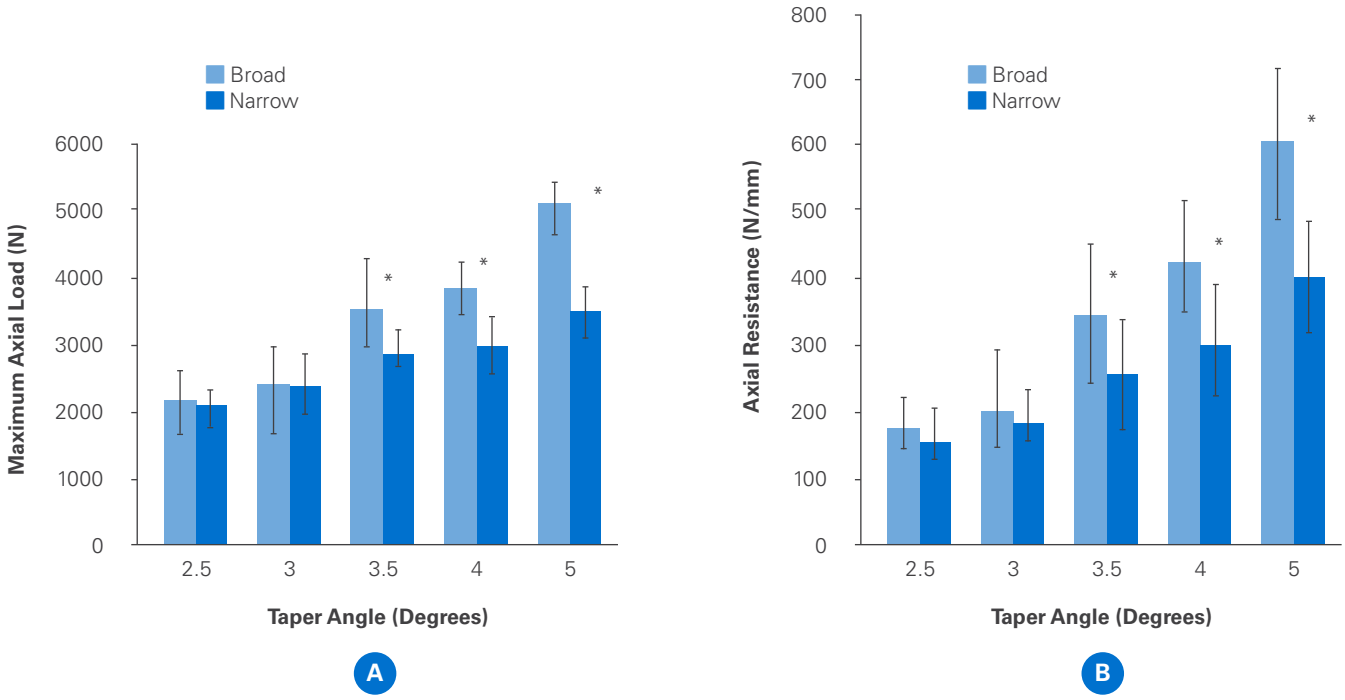

Figure 2. A)Least square mean values of peak load in axial testing. * Indicates statistically significant difference in peak load between broad and narrow spline geometries at the specified taper angle ($P < 0.05$). B) Least square mean axial resistance. * Indicates statistically significant difference between broad and narrow spline geometries ($P < 0.05$).

block at a rate of 0.5° per second until a peak rotation of 10° was reached. As with axial testing, repeated measures were conducted for a total of five trials per specimen. Torque, rotation and axial load data were collected from the load frame controller. Peak torque at 1° of stem rotation was quantified. Peak torsional resistance was measured as the linear slope of the rotation-torque curve within the first 0.2° of stem rotation within the foam block.

The mean diameter of the 3.5° taper at the most proximal point of implantation in our foam model is 15.5mm. By calculating the length of the arc created at the perimeter during component rotation around the central axis, it was determined that a 1° rotation of the test specimen equates to a 140µm relative micromotion between the spline and the foam model. Because micromotion at the stem-bone interface greater than 150µm at any aspect in the component may inhibit bone ongrowth and proper biological fixation,[16] evaluating the rotational stability at this small rotational increment was deemed helpful in order to identify any subtle differences in stability between designs at the level of micromotion critical to bone ongrowth.

In summary, we evaluated two metrics of both axial and rotational stability as derived from load frame displacement, load and torque transducers. Higher observed values in maximum axial load, the load required to generate 15mm of subsidence, along with the axial resistance, the load required per 1mm of subsidence, serve to indicate a more axially stable construct. Likewise, higher observed values in peak torque, the torque required to induce 1° of stem rotation, and axial resistance, the torque required per degree of rotation at the first 0.2° of rotation, serve to indicate increased rotational stability in the stem design.

Statistical analysis was performed utilizing repeated-measures multivariate linear regression techniques. For both axial and rotational tests the spline geometry, taper angle, and the interaction between each were analyzed for covariance. Least square means were derived for each test response for comparison between combinations of spline geometry and taper angle. A *P*-value or less than 0.05 was considered statistically significant. Our study was adequately powered (with power = 0.80, two-sided alpha = 0.05, and beta [probability of type II error] = 0.20) to detect differences between designs in means of 600 N maximum axial load

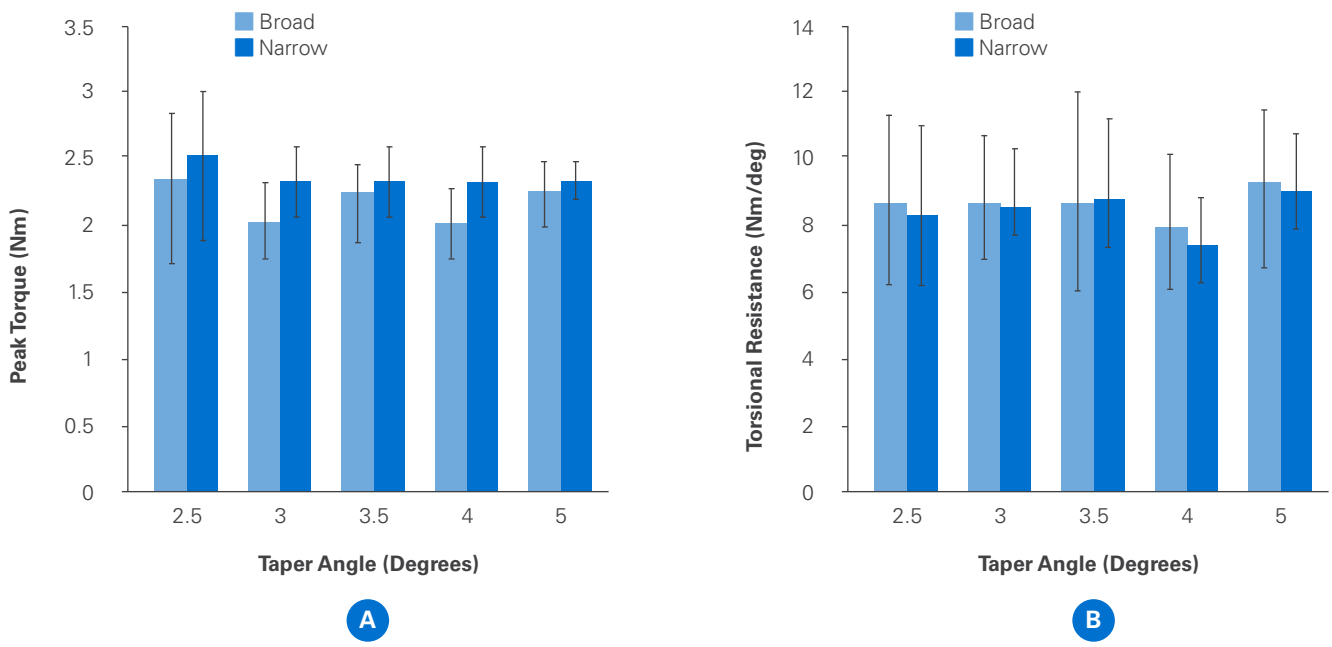

Figure 3. A) Mean peak torque required to generate 1.0° of rotational displacement. In the repeated-measures multivariate linear regression, spline design was a significant covariate with the narrow spline averaging a 9 percent greater peak torque across all taper angles (P = 0.0005). B) Mean calculated rotational resistance as observed in torsional testing. No statistically significant difference was detected between broad and narrow spline geometries at any taper angle tested.

and 100 N/mm of axial resistance in axial tests, as well as differences of means of 0.2 Nm or peak torque and 0.8 Nm/deg of axial resistance.

RESULTS

The broad spline design produced significantly higher maximum compressive loads than the narrow spline design taper angles of 3.5°, 4°and 5°, representing an increase in axial stability over narrow splines of 33 percent, 42 percent and 32 percent respectively (P <0.0001) (Figure 2A). Within both the broad and narrow spline configuration, the smallest maximum compressive load was observed within stems with taper angles of 2.5° and 3°. Overall, stem specimens with broad spline configurations and a 5° taper angle exhibited 21 percent-137 percent greater axial stability than the other spline combinations (P < 0.0001). There was found to be an overall greater than additive effect when considering the interaction between design and taper angle (P < 0.0001). Simply put, a greater difference in maximum axial stability between broad and narrow design was observed at higher taper angles. As a second measure of axial stability, axial resistance closely corresponded with maximum compressive load data (Figure 2B). In this measure of axial stability, the broad splines exhibited significantly higher axial resistance than the narrow splines at 3.5°, 4° and 5° of 37, 51, and 56 percent respectively (P < 0.0017). Overall, the 5° broad stem designs exhibited a 36-269 percent greater axial resistance than the geometry and taper angle combinations tested (P < 0.0001). In the axial resistance model, as with the axial compressive load model, a greater than additive effect was observed when considering the interaction between spline geometry and taper angle, with increasing influence of design at greater taper angles (P = 0.0001).

Rotational stability was determined as the greatest torque recorded during testing at a stem rotation of less than 1.0°, as well as the peak rotational resistance during the initial stem rotation. Maximum torque required to rotate each spline 1.0° is shown in Figure 3A. In the repeated measures multivariate linear regression accounting for all taper angles, the narrow spline design demonstrated a small, yet statistically significant, trend of 4-15 percent higher maximum torque required to generate 1.0° of stem rotation (P = 0.0018). Torsional resistance, representing a relative initial stiffness of the spline seating interface, is shown in Figure 3B. Neither taper angle nor spline

Table 1. Design Factors of Currently Available Tapered, Splined Modular Titanium Stems

	Stem A	Stem B	Stem C	Stem D	Stem E	Stem F
Taper angle	2°[17]	2°[18] (measured template)	2°[19] (measured template)	2.5°[20]	3°[21]	3.5°[22]
Taper length	104mm[17]	Variable (inferred: 85-190mm)[23]		Variable (inferred:101- 251mm)[24]	Variable (inferred:145-185mm)[25]	105mm[22]
Spline quantity	8[17]	Size 12:8 Size 25:10 (measured specimen)	Size 17:8 (measured specimen)	Size 14-ISmm:6 Size 16-21mm: 8 Size 22-31mm: 10[24]		8 (estimated)[26]
Spline height	1-2.9mm (sizes 19-25mm eight increases fro proximal to distal)[17]	2mm (1.5mm on size 14)[27]	1.5mm (measured specimen)			0.75mm[26]
Spine width		1mm (measured specimen)	0.5mm (measured specimen)			Sharp design[26]

geometry exhibited a significant overall effect on torsional resistance with the exception of an small outlier, the 4.0° tapered specimens, which exhibited slightly lower torsional resistance in both broad and narrow splines than the other taper angles ($P < 0.0001$).

DISCUSSION

Initial mechanical stability is a critical factor in achieving bone ongrowth and long-term success of revision THA. TSMTSs have been developed to promote high initial stability in cases of proximal bone deficiency, while reducing risk of thigh pain and intraoperative fracture when compared with other revision stem designs and philosophies. The literature contains very little of the design rationale for key elements in the design features of TSMTS. In particular, the design elements of taper angle and different spline geometries have not been well studied and vary significantly in the TSMTS currently on the market (Table 1).The purpose of the current study was to evaluate the effect of different taper angles and spline geometry on the initial mechanical stability of the implant. Specifically, we asked if differences in spline geometry and stem taper angle result in differences in (1) axial implant stability, and (2) stability to torsional stresses in a simulated revision THA with significant femoral bone loss.

We recognize limitations associated with the methodology and clinical extrapolation of our findings. First, we utilized a non-physiological polyurethane foam model as a substitute for a dynamic *in vivo* environment. This high-density foam is the basis for mechanical bench testing for cortical screw pull-out testing, and is commonly used in the literature as a bone substitute, but has not been validated as behaving similarly to cortical bone in the femoral diaphysis. Nevertheless, the use of a foam model enables tight control of interspecimen variability, a common problem with cadaveric testing, providing a uniform medium to compare relative differences in stem design factors while holding all other variables constant. Second, a single material density, length of engagement, reaming and insertion procedure were used in this study, while clinical bone density, degree or fixation and interference fit vary widely clinically. Surgical technique in terms of canal reaming and implant insertion also varies in revision surgery and is dictated primarily by bone quality and surgeon preference. Homogenization of these factors provides a baseline for comparative study of the key parameters while minimizing uncontrolled ancillary interactions. Third, we performed quasi-static mechanical tests evaluating peak rotational stability while in vivo, stem loading is predominately dynamic and cyclical. Aseptic loosening and subsidence are clinically related to micromotion at the bone-implant interface, and as such, the quantification of initial axial and rotational stability generates a baseline of overall mechanical resistance to component migration for each stem design.

Initial axial stability is a key factor in long-term success of revision total hip arthroplasty, particularly in the scenario of poor proximal bone quality.

Subsidence in TSMTS has been reported in a number of follow-up studies and can become more likely as bone quality diminishes[5, 14, 15, 28-30]. In a recent study, Van Houwelingen et al.[30] reported a five to 10 year survivorship, or 90 percent, for ZMR® (Zimmer, Warsaw, IN) TSMTS implanted in severe femoral defects. In seven of the 65 stems implanted, component subsidence of a mean 12.3mm was measured; however, all of those implants retained secondary stability and did not require re-revision. The authors of the study hypothesized that the reason for this secondary stability to be the 3.5° stem taper angle, compared to the common 2° taper angle in other TSMTS designs. Bolstering that hypothesis, Park et al[5] reported subsidence in five of 59 TSMTS implantations of the 2° tapered Lima modular femoral stems (Lima-Lto, Udine, Italy), with three re-revisions resulting from subsidence of 10-20mm. Similarly, in the 2° tapered Wagner stem (Zimmer, Warsaw. IN) a subsidence of greater than 10mm has been reported from 15[28] to 20 percent,[14,16] resulting in re-revision rates of 6[16] to 10 percent[28] in those subsided stems. However, it is important to remember that there are numerous factors that determine implant stability, with taper angle being one important factor. No taper angle will accommodate for poor surgical technique where intimate cortical contact is not achieved.[31] The current study reports substantially increased axial resistance and stability with increased taper angle. Though numerous factors are present which lend to implant stability, these data support the hypothesis that increased taper angle is associated with decreased subsidence and improved implant stability. The current literature lacks any discussion of TSMTS spline geometry; however, our results tend to show a paired increase in axial stability between taper angle and broad spline geometry.

The current study reports substantially increased axial resistance and stability with increased taper angle.

In addition to axial resistance to subsidence, rotational stability is a key aspect to resisting aseptic loosening in total hip arthroplasty. A few biomechanical studies have documented the impact of distal stem geometry on rotational stability in comparisons between cylindrical and fluted stems. In a cadaveric study, Kirk et al. observed a 27 percent greater resistance to component micromotion in the Link MP TSMTS compared to a cylindrical cobalt stem, however micromotions in both designs were well below the threshold at which osteointegration would be inhibited.[32] Jakubowitz et al.[33] quantified primary rotational stability between conical and cylindrical revision stems, with the Wagner-SL (Zimmer, Warsaw. IN) and MRP (Peter Brehm GmbH, Weisendorf, Germany) conical stems generating up to 96 percent less mean overall movement in synthetic femurs

with type III defects. Likewise, in an early biomechanical study, Kendrick et al. observed significantly higher torsional stability in cementless fluted stems over porous-coated , finned and slotted finned designs.[34] While these studies have demonstrated increased stability of TSMTSs over their counterparts, no differentiation in the literature has been made investigating spline design and taper angle in relation to rotational stability. The current study indicates that spline geometry does minimally influence rotational stability in some aspects, but not nearly to the degree that it affects axial subsidence. The narrow spline seems better able to "dig" into the substrate and slightly improve resistance to rotational instability, however the increase in peak torque resistance of less than 0.5 Nm observed in this study is unlikely to generate a clinically significant result.

The authors have considerable experience with cylindrical, extensively porous coated implants in revision total hip arthroplasty. Our experience, as well as the literature, has been very good with this revision strategy, with the notable exception of dealing with Paprosky types 3B and 4 femora. In these highly damaged bones, cylindrical extensively porous coated implants are technically demanding to implant and have a high failure rate due to lack of osseointegration. Because of this experience, we began to use tapered, splined stems in these challenging cases with much more favorable results. Having successfully used this reconstructive strategy on these highly damaged femora, we began to expand our use of tapered, splined stems on more revisions, including those femora with less damage (Paprosky 1-3A), also with excellent results. Our experience seems to parallel many other surgeons as the use of tapered, splined implants has grown significantly in the market. In fact, some of the authors now use tapered, splined stems for all revision femoral reconstructions. We think it is highly likely that there will be continued increase use of tapered, splined stems in revision total hip arthroplasty as more surgeons gain experience with them and the design of these implants is optimized.

In conclusion, our results demonstrate that taper angle and spline geometry are important variables in achieving initial mechanical stability as measured by resistance to stem subsidence, particularly with respect to axial stability. Specifically, higher degrees of taper angle (5° taper angle) and a broad spline geometry are superior to lower taper angles and a narrower spline geometry. In terms of rotational stability, taper angle demonstrates no repeatable influence, while a narrow spline geometry exhibits minimal improvement in tolerance to peak torsional when compared to broad spline designs. Differences in axial stability between taper angles may explain some of the clinical differences (and stem subsidence rates) that are reported in the literature with TSMTS. Additionally, these data are helpful when evaluating revision stems of this general type that are currently available to surgeons and provide guidance on the development of future tapered, splined modular titanium stems. •

Reprinted from The Journal of Arthroplasty, Volume 30, Number 7, July 2015, Pages 1254-1259, with permission from Elsevier.

REFERENCES

1. **Koster G, Walde TA. Wiiiert HG.** Five-to-10 year results using a noncemented modular revision stem without bone grafting. *J Anhroplasty* 2008:964.

2. **D, Eliaz N, Levi O, Backstein D, Kosashvili Y, Safir O, Gross AE.** Fracture of cementless femoral stems at the mid-stem junction in modular revision hip arthroplasty systems, *J Bone Joint Surg* 20 11;93-A:57.

3. **Munro JT, Garbuz OS, Masri BA, et al.** Role and results of tapered fluted modular titanium stems in revision hip arthroplasty. *J Bone Joint Surg* 2012:94-B:58.

4. **Palumbo BT, Morrison KL, Baumgarten AS, et al.** Results of revision total hip arthroplasty with modular, titanium-tapered femoral stems in severe proximal metaphyseal and diaphyseal bone loss. *J Arthroplasty* 2013;28:690.

5. **Park VS, Lee JH, Park JH, et al.** A distal fluted, proximal modular femoral prosthesis in revision hip arthroplasy. *J Arthroplasty* 2010;25.932.

6. **Garbuz OS, Toms A, Masri BA et al.** Improved outcomes in femoral revision arthroplasty with tapered fluted modular titanium stems. *Clin Orthop Relat Res* 2006;453:199.

7. **McInnis OP, Home G, Devane PA.** Femoral revision with a fluted, tapered, modular stem: seventy patients followed for a mean 39 years. *J Anhroplasty* 2006;21:372.

8. **Ovesen O,Emmeluth C, Hofbauer C, et al.** Revision total hip arthroplasty using a modular tapered stem with distal fixation: good short-term results in 125 revisions. *J Arthroplasty* 2010;25 :348.

9. **Park Y, Moon Y, Lim S.** Revision total hip arthroplasty using a fluted and tapered modular distal fixation stem with and without extended trochanteric osteomy. J Arthroplasty 2007;22(7): 993.

10. **Restrepo C, Mashadi M, Parvizi J. et al.** Modular Femoral sterns in revision total hip arthroplasty. *Clin Orthop Relat Res* 2011;469(2):476.

11. **Richards CJ, Duncm CP, Masri BA, et al.** Femoral revision hip arthroplasty: a comparison of two stem designs. *Clin Orthop Relat Res* 2010;468:491.

12. **Rodriguez JA, Fada R, Murphy SB, et al.** Two-year to five-year follow-up of femoral defects in femoral revision treated with the Link MP modular stem. *J Arthroplasty* 2009; 24(5):751.

13. **Schuh A, Werber S, Holzwarth U, et al.** Cementless modular hip revision arthroplasty using the MRP Titan Revision Stem: outcome of 79 hips after an average of 4 years' follow-up. *Arch Orthop Trauma Surg* 2004;124(5):306.

14. **Böhm P, Bischel O.** Femoral revision with the Wagner SL revision stem. *J Bone Joint Surg* 2001;83A:I023.

15. **Rodrguez JA, Deshmukh AJ, Klauser WU, et al.** Patterns of osseointegration and remodeling in femoral revision with bone loss using modular, tapered, fluted, titanium stems. J *Arthroplasty* 2011;26(8):1409.

16. **Pilliar RM, Lee JM, Maniatopoulos C.** Observations on the effect of movement on bone ingrowth into porous surface implants. *Clin Orthop Relat Res* 1986;208:108.

17. Zimmer, Inc. Wagner SL Revision® Hip Stem Surgical Technique; 2009.

18. **Kwong LM.** Surgical Technique with the MPDI Hip Stem for Revision of a Failed Femoral Hip Stem. Link Orthopaedics 2002.

19. Stryker Orthopaedics. Restoration® Modular Revision Hip System: Surgical Protocol; 2005.

20. DePuy Orthopaedics. Reclaim® Revision Hip System Design Rationale; 2011.

21. Biomet, Inc. Arcos® Modular femoral Revision Stem. Undated; 2011.

22. Zimmer. Inc. ZMR® Hip System: 2009.

23. Link Orthopaedics.MP® Reconstruction Prosthesis: Cementless & Cementable Implants & Instruments; 2011.

24. DePuy Orthopaedics. Reclaim® Revision Hip System Operating Room Reference Guide: 2011.

25. Biomet, Inc.. Arcoc® Modular Femoral Revision System: Surgical Technique; 2011.

26. Zimmer. Inc. ZMR® Revision Taper Hip Prosthesis: Surgical Technique for Revision Hip Arthroplasty; 2002.

27. Link Orthopaedics. The MP® Hip Stem Design Rationale; 2009.

28. **Grunig R. Morscher E, Ochsner PE.** Three- to 7-year results with the uncemented SL femoral revision prosthesis. *Arth Onhop Trauma Surg* 1997;116:187.

29. **Kolsd K, Adalberth G, Mallmin H, et al.** The Wagner revision stem for severe osteolysis. 31 hips followed for 1.5-5years. *Acta Orthop Scand* 1996;67:541.

30. **Van Houwelingen AP, Duncan CP, Masri BA, et al.** High survival of modular tapered stems for proximal femoral bone defects at 5 to 10 years follow up. *Clin Orthop Relat Res* 2013;471:454.

31. **Patel PO, Klika AK. Murray TG, et al.** Influence of technique with distally fixed modular stems in revision total hip arthroplasty. *J Arthroplasty* 2010;251(6):926.

32. **Kirk KL, Potter BK, Lehman Jr RA, et al.** Effect of distal stem geometry on interface motion in uncemented revision total hip prostheses. *Am J Orthop* 2007 :36(10):545.

33. **Jakubowitz E, Bitsch RG, Heisel C, et al.** Primary rotational stability of cylidrical and conical revision hip stems as a function of femoral bone defects: an in vitro comparison. *J Biomech* 2008;41.3078.

34. **Kendrick JB, Noble PC, Tullos HS.** Distal stem design and the torsional stability of cemetless femoral stems. *J Arthroplasty* 1995;10(4):463.

MONOBLOC REVISION FEMORAL STEM: FIRST CASES

Jose Rodriguez, MD
Lenox Hill Hospital

A 77-year-old female with severe osteoporosis and a contraindication for cement received Exactech's Alteon® Monobloc Revision Femoral Stem through a tableless anterior approach. In this complex primary case a 54mm Novation® CrownCup®, 25mm Alteon Bone Screw, 36mm neutral Connexion GXL® liner, and +0mm BIOLUX®*delta* head accompanied the 20x195mm Monobloc Revision Femoral Stem implant. Intraoperatively, the final implant achieved axial stability at a level 1mm proud of the location predicted by the stem trial. •

Michael Kang, MD
Insall-Scott-Kelly Institute for Orthopedics and Sports Medicine

A 66-year-old male with an infected primary hip implant received Exactech's Alteon Monobloc Revision Femoral Stem through the posterior approach as a part of a two stage revision. In this case a 62mm multi-hole InteGrip® shell, two Alteon Bone Screws, a 36mm lipped Connexion GXL liner and a -3.5mm cobalt chrome femoral head accompanied the 24x195mm Monobloc Revision Femoral Stem implant. •

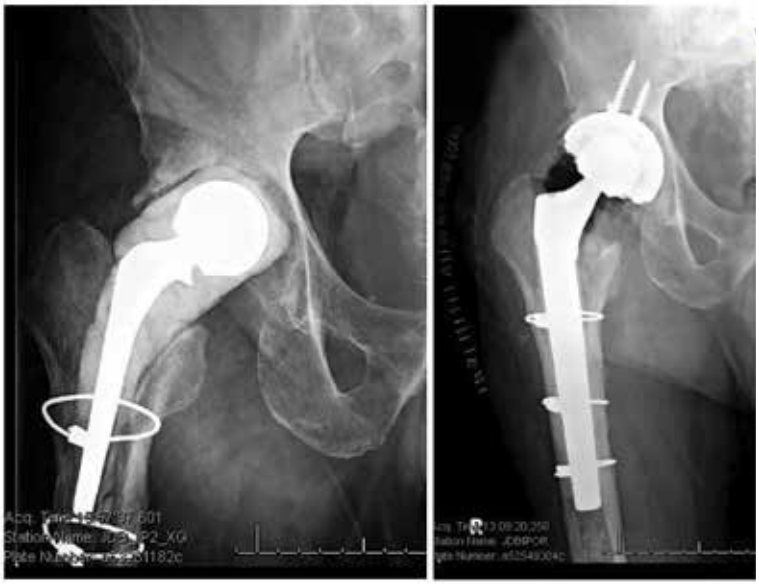

REVISION OF THE LOOSE GLENOID COMPONENT IN ANATOMIC TOTAL SHOULDER ARTHROPLASTY

Pierre-Henri Flurin, MD
Clinique du Sport Bordeaux-Mérignac

Martin Janout, MD
Northwest Orthopaedic Specialists

Christopher P. Roche, MS, MBA
Exactech, Inc.

Thomas W. Wright, MD
University of Florida College of Medicine

Joseph Zuckerman, MD
NYU Hospital for Joint Diseases

www.exac.com/courses

July 15 | Mastering Glenoid Exposure, the Reverse Shoulder and the Challenging Glenoid **| San Francisco, Calif.**

Loosening of the glenoid component is a frequent cause of failure of total shoulder arthroplasty (TSA).[1,2] The etiology of glenoid loosening is multifactorial, including aseptic osteolysis, rotator cuff insufficiency and the so-called rocking horse phenomenon,[3] soft tissue instability (leading to increased edge-loading), and infection. A loose glenoid component is frequently associated with substantial loss of glenoid bone stock, necessitating additional procedures in order to implant a new component. Several studies have shown that patients with a new glenoid component have better clinical outcomes, which makes successful glenoid reimplantation a priority.[4-6]

The goal of this review is to discuss the reconstructive options when treating a loose glenoid component in anatomic total shoulder arthroplasty (aTSA). These include the established techniques of reaming the high side or bone grafting the deficient glenoid, along with a one or two stage revision. Recently, new approaches to revision have been investigated, including the use of reverse total shoulder arthroplasty and augmented glenoid components. Finally, the ream-and-run procedure remains the last resort option in the face of significant glenoid bone defects. Infection is frequently associated with glenoid component loosening.

Although some of the concepts discussed here apply to an infected TSA, its management is beyond the scope of this article and will not be specifically addressed.

DIAGNOSIS OF A LOOSE GLENOID COMPONENT

The diagnosis of a loose glenoid component relies on identifying significant or progressive lucency surrounding a glenoid component in the context of ongoing pain. Lucent lines associated with the glenoid component following total shoulder arthroplasty are commonly reported, especially with the progression of time, and range between 30 and 84 percent.[7-13] However, no definite causal relationship between their presence and clinical loosening has been established.[14] The true rate of clinical failure and revision TSA due to a loose glenoid is lower than the rate of postoperative radiographic

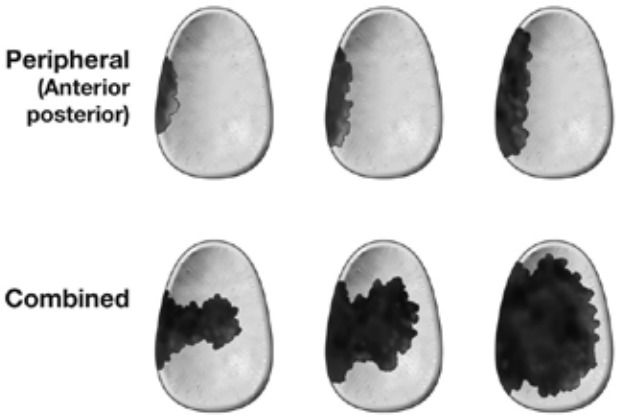

Figure 1. The Antuna Classification of glenoid bone loss.

lucent lines and is reported between 3 and 10 percent.[1,7,12,15-17]

Glenoid lucent lines are classified according to Deutsch's modification of Souter's classification system into six grades: Grade 0, for no radiolucent line; Grade 1, radiolucent line less than 1mm wide and incomplete; Grade 2, radiolucent line 1mm wide and complete; Grade 3, radiolucent line 1.5mm wide and incomplete; Grade 4, radiolucent line 1.5mm wide and complete; and Grade 5, radiolucent line 2mm wide and complete. A radiographically loose glenoid component is characterized by: 1) a circumferential radiolucent line of at least 2mm around the glenoid component; 2) progression of radiolucent lines on serial radiographs; 3) presence of cement fragmentation; and 4) gross component migration.[5]

OPERATIVE MANAGEMENT OF THE FAILED GLENOID

The preoperative workup of a patient with suspected glenoid component loosening begins with a careful history and physical examination. The presence, duration, and character of pain is elicited, as well as any previous incisions and signs of rotator cuff and deltoid atrophy. Active and passive range of motion and a complete neurovascular exam are performed. Standard radiographs consisting of a true AP view of the scapula in neutral, internal and external rotation, along with scapular profile and axillary view help evaluate for presence of periglenoid lucencies, glenoid component shift, superior migration of the proximal humerus, and bone defects. CT scan is often helpful in providing greater detail about glenoid bone stock and version to assist with preoperative planning. Infection has to be considered in every case of a suspected loose glenoid component. Complete blood count with differential, erythrocyte sedimentation rate, and C-reactive protein levels should be obtained. Aspiration of the joint can be helpful if the clinical picture is suspicious for infection. Intraoperatively, frozen section specimens can be analyzed for signs of acute inflammation.[18]

Operative management typically utilizes the deltopectoral interval. In revisions, extensive soft tissue scarring is expected, and the anatomical landmarks are less evident. It is important to release adhesions in the subdeltoid and subacromial spaces. The coracoid process is identified, and the remainder of the clavipectoral fascia is incised along the lateral aspect of the conjoint tendon. The subscapularis is tenotomized or released with its bony insertion, followed by its careful mobilization. CA circumferential glenoid capsular release is performed while protecting the rotator cuff. If present, tenotomy or tenodesis of the long head of the biceps is performed. The axillary nerve at the inferior aspect of subscapularis must be protected during dissection in this area.

The different options for managing glenoid bone defects include use of a cancellous or corticocancellous/structural bone graft, whether to implant a new glenoid as part of a one stage or two stage revision, and whether rotator cuff insufficiency will require the use of a reverse prosthesis. The advantage of a one stage procedure is avoiding the surgical morbidity of a second surgery. The downside to this

Figure 2. Eccentric reaming (left) removes the "high side bone" to restore glenoid version. Off-axis reaming (right) can minimize the amount of glenoid bone removal when combined with an augmented glenoid.

approach is a potential for loosening of a glenoid component that is supported by unincorporated bone graft due to graft resorption. The choice of cancellous versus structural bone graft largely depends on surgeon preference and the type of glenoid defect. In multiple clinical studies, it has been demonstrated that graft subsidence is frequent, approaching 100 percent in some series.[20,21] The degree of subsidence has been reported as up to 14mm or more.[21] Rotator cuff insufficiency is a frequent cause of glenoid loosening that leads to TSA revision.[3] Therefore, the treating surgeon has to be prepared to perform soft tissue reconstruction or a reverse total shoulder arthroplasty, in addition to glenoid reconstruction. The reconstructive ladder, in order of increasing complexity, includes simple glenoid reimplantation, eccentric reaming along with standard glenoid implantation, augmented glenoid with or without eccentric reaming, bone graft reconstruction with either one or two-stage glenoid reimplantation, and reverse total shoulder arthroplasty (rTSA). In a situation of catastrophic glenoid bone loss a hemiarthroplasty may be the best (and only) option. Patient's age and activity level must also be considered and integrated into the surgical decision-making process.

TSA WITHOUT BONE GRAFT

Simple Glenoid Reimplantation

Occasionally, it is possible to revise the glenoid component without significant reconstructive measures, such as bone grafting or high side reaming. Patients with an acute infection or a traumatic event causing glenoid loosening are included in this category, which in turn represents the best-case scenario. After the removal of the loose component, attention must be paid to removal of all bone cement, if present, with as little damage as possible to the surrounding bone. This is followed by superficial reaming of the glenoid surface, sufficient to remove any fibrous tissue and to expose healthy subchondral bone. A new glenoid component is usually cemented using third generation cementing technique.[22] Both pegged and keeled components can be used in this situation. Typically, a removed pegged component can be revised to a pegged or keeled implant, depending on the condition of the previous peg holes. A failed keeled component is typically revised to another keeled component.

ECCENTRIC REAMING WITH STANDARD GLENOID IMPLANTATION

Eccentric reaming consists of lowering the glenoid surface opposite the site of peripheral erosion in order to re-establish natural glenoid version (Figure 2). It is reserved for peripheral and some combined glenoid defects, as classified by Antuna and coworkers.[4] It is imperative to preserve as much glenoid bone stock as possible, and therefore the utility of this technique is limited to small defects. Generally speaking, no more than 10° to 18° of retro- or anteversion can be corrected with this technique without narrowing the glenoid vault excessively and risking peg or screw penetration.[23,24] Excessive reaming of the unworn glenoid surface also results in joint line medialization, placing the rotator cuff and deltoid muscles at a mechanical disadvantage, and resulting in

Figure 3. Examples of augmented glenoid components. A) 8° Equinoxe posterior augment all-polyethylene pegged glenoid; B) 8° Equinoxe augmented baseplate for rTSA for use with anterior or posterior bone deficiency; C) Equinoxe standard and extended cage peg rTSA baseplates to facilitate bone grafting in the native glenoid; D) 10° Equinoxe superior augment rTSA baseplate for use with superior bone deficiency (Exactech, Gainesville, FL).

weakness. In a clinical series, Iannotti and associates[24] demonstrated that no more than 19° of glenoid retroversion could be corrected by high side reaming without glenoid vault perforation by the center peg. Similar findings were reported by Gillespie and colleagues,[23] who studied the effects of high side reaming on ability to implant a glenoid component in a cadaver model. After correcting 15° of retroversion by high side reaming, 50 percent of glenoids were not able to be implanted due to either insufficient bone support, peg penetration, or both. They concluded that 10° of retroversion is likely the limit that can be corrected with preferential anterior reaming.[23]

AUGMENTED GLENOID IMPLANTATION

The use of an augmented glenoid component is another means of compensating for glenoid bone loss and restoring normal anatomic glenoid version. Its use can be facilitated by simultaneous eccentric reaming or by off-axis reaming (Figure 2).[25-28] The different designs of augmented glenoids include implants with asymmetric thickness (increased toward the side of bone loss) and actual step-shaped glenoids (Figure 3). Such implants enable the surgeon to avoid reaming the high side excessively in order to restore neutral glenoid version and thereby minimize the amount of bone removal. One of the first clinical reports of using this technique was by Rice and coworkers.[27] The investigators implanted an augmented glenoid component in 13 patients with eccentric posterior glenoid erosion to restore neutral version. The component used was an all-polyethylene cemented keeled glenoid with asymmetric thickness in an anterior-posterior direction. The component was capable of correcting the slope of glenoid by approximately 4°. In a mean 5-year follow-up, the investigators reported 14 percent unsatisfactory results and concluded that although overall pain relief and improvement in function was satisfactory, instability was not always corrected. They concluded that the component did not offer any advantage over standard implants.[27] Recently, Iannotti and colleagues[25] revisited the topic of an augmented glenoid in a biomechanical study. They evaluated the resistance to loosening of four cemented augmented or step-glenoid designs when subjected to repetitive humeral head compression and translation. The investigators found the stepped design to have superior fixation and less implant liftoff in response to eccentric loading, when compared to the asymmetric designs, such as the one used in Rice's study.[25] However, asymmetric designs have been demonstrated to conserve more bone than stepped glenoid designs.[29]

In a cadaver study, Kirane and coworkers[26] tested two prototypes of posterior augmented glenoid implants (all polyethylene and metal-backed) in a simulated posterior-deficient glenoid (type B2). The investigators measured periglenoid bone strains for each implant under simulated physiologic loading conditions. No significant difference was found between the all polyethylene step-glenoid and a conventional implant in the absence of a defect, prompting the investigators to recommend further mechanical testing of the implant. The metal-backed component induced significantly increased periglenoid strains, potentially implying increased risk of bone resorption and loosening.[26] Youderian and

associates[28] reported on early clinical outcomes of 24 patients treated with a new step-glenoid design in primary TSA. Eighteen patients had a minimum follow-up of six months, and eight patients underwent a postoperative CT scan. The clinical outcome scores showed significant improvement in 17 of 18 (94 percent) cases. In the eight shoulders evaluated with the postoperative CT scan, the average glenoid version correction was 16.7°, which was significantly more than the 11.3° achieved by using a standard glenoid with asymmetric reaming in the comparison group. Joint line medialization was also avoided with the augmented design.[28] The mid- and long-term survivorship of these implants remains to be determined.

TSA WITH BONE GRAFT

One-Stage Reimplantation

One-stage bone grafting and implantation of a new glenoid component is frequently performed for contained or central glenoid defects amenable to cancellous packing. Small peripheral or combined defects that can be successfully reconstructed with high side reaming or a structural corticocancellous graft can also be managed in a one-stage revision. Immediate new glenoid implantation can be performed if sufficient glenoid rim and surface remains to support the glenoid trial and adequate cancellous bone remains to cement a new component.[30] Generally speaking, no more than 40 to 50 percent of a new glenoid should be supported by bone graft although biomechanical and clinical data on this subject are lacking.[5] Central glenoid defects are frequently managed with cancellous bone graft while the peripheral and combined defects are addressed with a combination of cancellous and structural bone graft.[31]

There is paucity of studies aimed specifically at evaluating one-stage reconstruction. Most reports include a mixed population of patients, some of which undergo one-stage glenoid revision with bone grafting. Elhassan and coworkers[6] reported on three out of 21 patients undergoing revision for a loose glenoid component who received a TSA. They reported good short-term outcome and the benefit of implanting a glenoid component over biologic resurfacing or bone graft only.[6] Cheung and associates[30] performed revision in 68 shoulders secondary to glenoid loosening. In 33 patients, new glenoid implantation was possible at the time of the revision procedure. The remaining 35 patients were revised to a hemiarthroplasty with glenoid bone grafting. The primary statistically significant benefit of glenoid reimplantation was the increase in forward elevation. There was also a trend toward greater patient satisfaction in the group with an implanted glenoid. The rate of revision-free survival at five years was not significantly different between the two groups. Ten years after revision, the revision-free survival rate was marginally higher in the new glenoid group compared to hemiarthroplasty. Overall, the results suggested that a new glenoid component should be implanted if structurally feasible.[30] On the other hand, Bonnevialle and associates[20] found a significant rate of radiographic loosening of a newly implanted glenoid. In their case series of 42 TSAs revised with or without bone grafting and a cemented PE glenoid, 28 out of 42 (67 percent) of the new bone grafted glenoids were radiographically loose at 74 months, with seven (17 percent) requiring second revision due to recurrent loosening. All 10 grafts placed during the original revision were partially or completely resorbed. The investigators postulated that placing the graft between the cortical bone of the glenoid vault and the cement mantle may not be the optimal biological environment to facilitate its healing. The investigators also cautioned about the high rate of soft tissue complications in the form of subscapularis insufficiency and rotator cuff tears in the revision scenario that may contribute to the high rate of failure.[20] Due to the potential problems associated with cementing a new glenoid into a bone-grafted bed, some investigators have preferred a metal-back ingrowth glenoid component. Valenti and colleagues[32] reported clinical outcomes of 10 shoulders revised for glenoid loosening in anatomic TSA at a minimal follow-up of two years. The investigators used a new metal-backed implant with a long central peg, superior and inferior screws, and an anterior plate for additional fixation of the bone graft. They reported overall improvement in clinical outcome scores and good integration of the bone graft without radiolucency or glenoid component loosening. There was one case of PE

> The investigators found the stepped design to have superior fixation and less implant liftoff in response to eccentric loading, when compared to the asymmetric designs.

liner dissociation. The investigators concluded that revision to a non-cemented glenoid component combined with bone graft can solve the problem of loosening as long as the rotator cuff is functional although the study population was small and the follow-up short.[32]

Two-Stage Reimplantation

Frequently, the surgeon is faced with bone loss of the glenoid surface or vault significant enough to preclude immediate glenoid reimplantation. In this situation, the loose glenoid component is removed, and all bony defects carefully debrided and bone grafted. Central contained defects are packed with cancellous bone while peripheral or combined defects are reconstructed with a combination of cancellous and structural graft. Currently, there does not appear to be a clear advantage to using either cancellous or cortico-cancellous bone graft in terms of graft incorporation and either serves to restore glenoid bone stock to enable future glenoid revision.[30] Clinical studies have demonstrated that many patients experience adequate pain relief following revision to hemiarthroplasty with glenoid bone grafting and do not require a delayed glenoid reinsertion.[33,34] Cheung and coworkers[33] reported on seven previously bone grafted patients undergoing glenoid reinsertion for persistent pain with an average follow-up of 79 months. The newly implanted glenoids were a mixture of bone-ingrowth, metal-backed with cement augmentation, and all-polyethylene cemented components. The investigators concluded that good pain relief can be achieved with delayed glenoid implantation, although range of motion cannot always be improved.[33]

Phipatanakul and Norris[34] reported on 24 patients undergoing revision TSA with removal of the glenoid component and bone grafting of the glenoid vault. Eighteen patients had adequate pain relief after the initial procedure, and four patients achieved good pain relief after a second stage glenoid implantation for persistent pain. Graft subsidence was reported in 10 out of 20 cases (50 percent) although it did not preclude placement of a new glenoid component during the second stage revision. Overall, the investigators found bone grafting of the glenoid beneficial in terms of pain relief (92 percent of patients) as well as enabling delayed glenoid implantation. However, range of motion did not improve significantly and graft subsidence rate was concerning.[34]

The unique mechanical design of the rTSA allows it to potentially address all of the anatomical deficiencies in one setting.

Antuña and associates[35] reported on three patients treated with glenoid implantation at a second stage. These patients previously underwent removal of a loose glenoid and bone grafting with cancellous allograft and experienced continued pain. At the time of re-revision, the investigators found the glenoid depth to be approximately 1cm, which was limited but sufficient to implant a new metal backed component. One patient had an excellent result at five years postoperatively, one satisfactory result at eight years, and one unsatisfactory result at two years with further need for glenoid revision.[35]

REVERSE TOTAL SHOULDER ARTHROPLASTY (rTSA)

The reverse total shoulder arthroplasty was designed to address the problem of cuff tear arthropathy and clinically has performed well for this indication.[36-38] In addition to bony glenoid deficiency, soft tissue complications, such as rotator cuff tears, subscapularis insufficiency, and implant instability, are frequently identified during revision TSA.[20,39] Revision to anatomic TSA with a deficient rotator cuff predictably leads to the so-called rocking horse phenomenon and glenoid component loosening.[3]

Similarly, use of a hemiarthroplasty in this scenario is at risk for developing anterosuperior subluxation in patients with previous acromioplasty andincompetent coracoacromial arch.[40] The unique mechanical design of the rTSA allows it to potentially address all of the anatomical deficiencies in one setting. Recently, the rTSA has been used to address the problem of glenoid loosening in TSA, particularly if associated with rotator cuff tears and uncontained large glenoid bone deficiency.[39,41,42] Melis and coworkers[39] reported on 37 anatomic TSAs revised to reverse prosthesis for aseptic glenoid loosening with a mean follow up of 47 months. Thirty-four out of 37 revisions were performed in one stage. Eighty-six percent of patients were either satisfied or very satisfied, and 76 percent (22/29) of the glenoid bone grafts healed. Functional gains were made mostly in terms of improving active elevation and reducing pain. External and internal rotation did not change. Eight patients (21 percent) required

further surgery due to complications, three of whom had recurrent glenoid loosening. The investigators concluded that rTSA is a reliable revision option and provides stable fixation of the underlying bone graft with the glenoid baseplate and screws. To achieve this, they prefer use of a long peg baseplate to reach native glenoid bone. However, the technique is demanding and associated with a significant rate of complications.[39]

Norris and colleagues[41] describe a novel technique of utilizing an rTSA baseplate fixed to the iliac crest before subsequently removing it with the portion of the ilium, which is then press fit into the glenoid defect. The entire construct is fixed into the scapular body and columns beyond the defect using an extra-long post and screws in the glenoid base plate. The common principle of the above techniques is fixation of the baseplate to the native glenoid while providing stable fixation of the bone graft to allow its incorporation. The bone graft serves to enhance baseplate fixation by being press fit into the glenoid defect. It also prevents excessive joint line medialization.[41] The latter can also be accomplished by using an extended offset/expanded glenosphere.

Patel and colleagues[42] recently reported on their series of 28 patients who underwent revision of a failed shoulder arthroplasty to a reverse prosthesis at an average 41 months follow-up. Among the cohort, there were eight failed TSAs, with the rest being failed hemiarthroplasty and rTSA. The etiology of failure of the original implants was heterogenous with implant loosening being reported in only three patients. The glenoid was bone grafted in four patients. The investigators reported overall significant improvement in all of the outcome measures (ASES, UCLA, SST, VAS scores), as well as forward elevation which increased 64° on average. Twenty-three patients (82 percent) rated their outcome as good, excellent, or satisfactory, and 5 patients (18 percent) rated their outcome as unsatisfactory. Three of the 28 patients (10.7 percent) had complications. Overall, the investigators concluded that the rTSA can provide increased shoulder motion, decreased pain, and improved functional outcomes in patients with all types of failed shoulder arthroplasty.[42]

Since patients with a failed anatomic TSA can present with a variety of glenoid deficiency, development of augmented glenoid baseplates in rTSA may prove valuable in the future.[43]

As in anatomic TSA, the rTSA comes with an option to implant an augmented glenoid component to compensate for asymmetric glenoid wear. In a recent biomechanical study, Roche and coworkers[43] simulated a superior glenoid defect treated either with eccentric reaming/standard baseplate or off-axis reaming/superior augmented baseplate (Figure 2). Both constructs were cyclically loaded and compared to a control implant with no glenoid defect. Each glenoid implant remained well fixed after cyclic loading with no statistically significant difference in displacement. Since patients with a failed anatomic TSA can present with a variety of glenoid deficiency, development of augmented glenoid baseplates in rTSA may prove valuable in the future.[43] The reverse shoulder arthroplasty should be used with caution in the revision scenario as long-term survivorship is not well known in a homogenous patient population. It should be reserved for patients 65 years and older. Long-term follow-up is needed to analyze the incidence of some of the documented complications, such as scapular notching and instability.

HEMIARTHROPLASTY

With Glenoid Bone Graft

Revision to hemiarthroplasty (HA) is considered when faced with glenoid bone defect substantial enough to preclude immediate glenoid reimplantation. It can provide a definitive solution, particularly in an older, low demand patient wishing to avoid further surgery. For other patients, it represents the first stage of a two-stage TSA revision with the eventual goal being anatomic or rTSA. The status of the rotator cuff and patient's age will help determine if a TSA or rTSA will be the final implant of choice. Grafting the glenoid bone deficiency restores the bone stock needed for future glenoid implantation.[30] It also prevents excessive joint line medialization and results in significantly improved outcomes with respect to pain, mobility, and shoulder function when compared to revision without bone grafting the glenoid deficiency.[30,44] Finally, multiple clinical studies of primary hemiarthroplasty performed for osteoarthritis indicate superior results in terms of function and level of comfort when performed

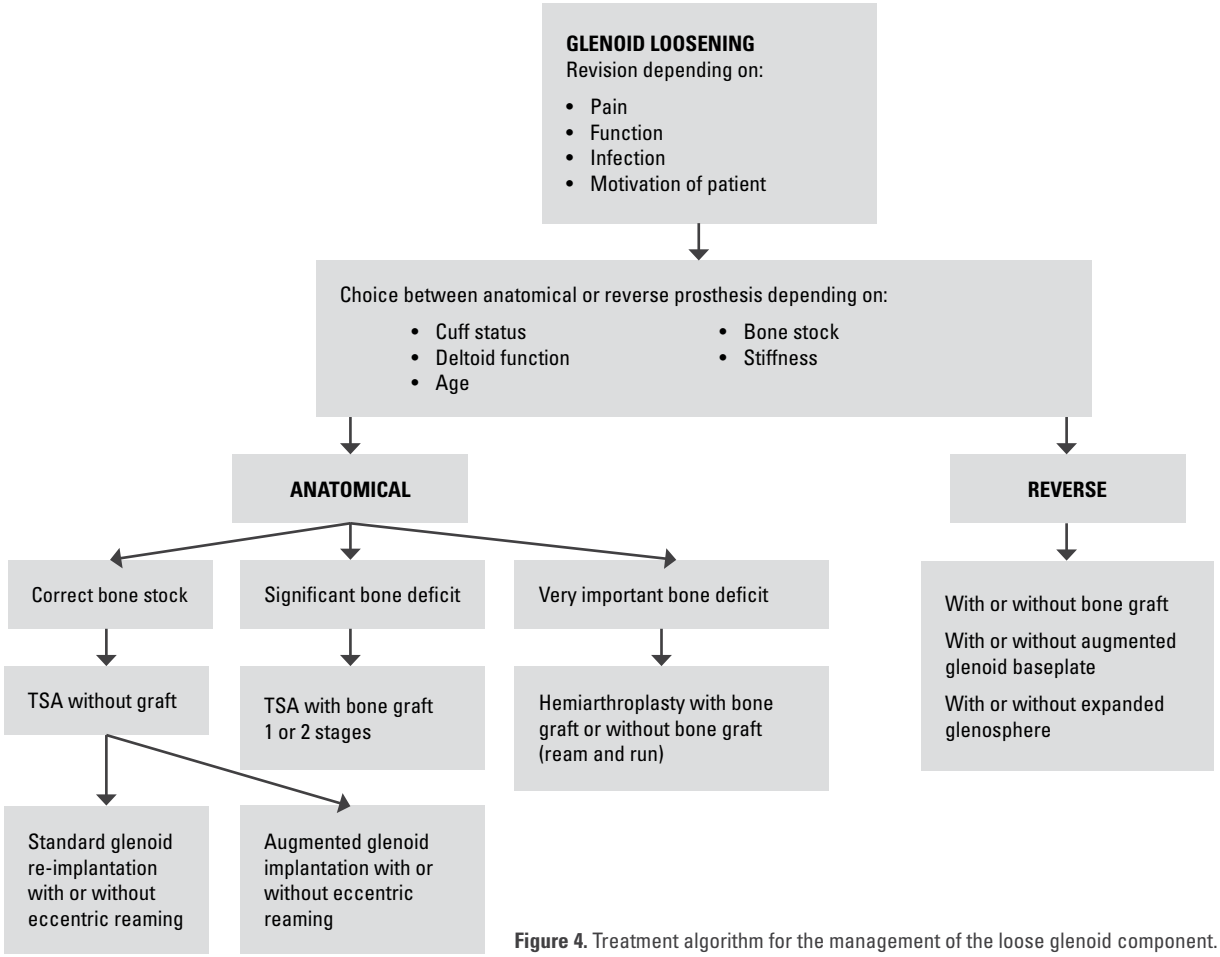

Figure 4. Treatment algorithm for the management of the loose glenoid component.

without eccentric glenoid wear.[45,46] Therefore, it would stand to reason that correcting any eccentric glenoid wear by a combination of reaming and bone grafting would result in improved clinical results in a revision situation.

Neyton and coworkers[47] reported on nine patients undergoing TSA revision for a loose glenoid component with bone loss significant enough to prevent new glenoid implantation. The glenoid defects were reconstructed using iliac crest bone grafting with modification of positioning the bicortical graft such that the cortical surface faced laterally. In a mean follow-up of 30 months, the clinical outcome was considered satisfactory in five and unsatisfactory in four patients.[9] The mean graft subsidence was 4.1mm. Two cases that were observed to have 10mm and 11mm medialization were also found to have anterior-superior migration of the humeral head suggestive of a massive rotator cuff tear. Only one patient decided to undergo additional surgery. He was revised to a reverse total shoulder due to a massive cuff tear. Intraoperatively, solid graft incorporation was found, enabling stable fixation of the glenosphere. The investigators concluded that adequate pain relief and glenoid bone stock restoration could be achieved with removal of the loose glenoid combined with bone graft.[47] This procedure also prevented excessive joint line medialization provided the rotator cuff was intact. However, functional outcomes in terms of motion did not improve.

Scalise and Iannotti[21] revised 11 failed TSAs to a hemiarthroplasty combined with bone grafting of glenoid defects. They used cancellous allograft to fill the void of central/contained defects, and structural graft to reconstruct peripheral or combined defects. At a minimum two-year follow-up the investigators noted overall improvement in clinical outcome scores. All the grafts showed some degree of resorption, with eight of the 11 patients experiencing graft subsidence greater than 5mm. Greater subsidence was seen in structural grafts (mean 14mm) than in cancellous graft (mean 7mm). The ingvestigators concluded this difference in subsidence was likely due to lack of a supporting cortical rim in defects treated with structural graft, rather

than the type of graft used. The presence of graft subsidence, although concerning, did not influence the clinical outcome scores.[21]

HA WITHOUT GLENOID BONE GRAFT (REAM-AND-RUN PROCEDURE)

The ream-and-run procedure has been used with clinical and radiographic success in shoulder reconstruction. It addresses significant glenoid bone loss with reaming the glenoid to a slightly larger radius of curvature than a newly implanted humeral head. Matsen and associates[48] describe this procedure and consider it a reconstructive option in patients wishing to avoid the risk of glenoid loosening.[48] There is paucity of literature on the use of this technique in revision TSA. The outcome data reported is primarily associated with primary arthroplasty. Lynch and colleagues[49] found significant improvement in self-assessed pain and function at a two-year follow-up using this technique in 37 patients. The final functional outcome of patients with preoperative glenoid wear was equal to the patients without preoperative glenoid wear. Better outcomes were observed in patients who developed a lucency between the humeral component and the reamed glenoid surface on their final follow-up radiograph, suggesting some degree of joint surface regeneration.[49]

> The augmented glenoid components may allow surgeons to limit eccentric reaming and the extent of bone grafting necessary in a glenoid with bone deficiency.

Gilmer and colleagues[50] analyzed the factors prognostic for clinical improvement following the ream-and-run procedure in 176 patients. They concluded the patients with the most favorable outcome were men over 60 years old with no previous surgery, primary shoulder osteoarthritis, a preoperative SST score greater than or equal to five, and those who underwent surgery after 2004.[50] In a revision situation, the ream-and-run procedure can serve as a last resort option for a surgeon facing a severely deficient glenoid without the possibility of bony reconstruction.

CONCLUSION

Revision of a loose glenoid component in TSA poses a surgical challenge. The literature available on this subject indicates an advantage to implanting a new glenoid component. However, the correct timing of new glenoid implantation is not clear. It may be preferable to bone graft any existing glenoid bony deficiencies and reserve glenoid reimplantation for a later stage if continuing symptoms indicated the need for further revision. Bone grafting also restores the natural joint line and kinematics. The augmented glenoid components may allow surgeons to limit eccentric reaming and the extent of bone grafting necessary in a glenoid with bone deficiency. The reverse total shoulder arthroplasty is emerging as a useful reconstructive tool capable of addresing bony and soft tissue problems encountered in revision TSA. The increasing use of augmented glenoids and rTSA in revision TSA provides opportunities for more clinical outcomes research on this important subject (Figure 4). •

Reprinted from the Bulletin of the Hospital for Joint Diseases, Volume 71, Supplement 2, 2013 p. 568-576 with permission.

REFERENCES

1. **Buckingham BP, Parsons IV M, Campbell B, et al.** Patient functional self-assessment in late glenoid component failure at three to eleven years after total shoulder arthroplasty. *J Shoulder Elbow Surg.* 2005 Jul-Aug;14(4):368-74.

2. **Franta AK, Lenters TR, Mounce D, et al.** The complex characteristics of 282 unsatisfactory shoulder arthroplasties. *J Shoulder Elbow Surg.* 2007 Sep-Oct;16(5):555-62.

3. **Franklin JL, Barrett WP, Jackins SE, Matsen III FA.** Glenoid loosening in total shoulder arthroplasty. Association with rotator cuff deficiency. *J Arthroplasty.* 1988;3(1):39-46.

4. **Antuna SA, Sperling JW, Cofield RH, Rowland CM.** Glenoid revision surgery after total shoulder arthroplasty. *J Shoulder Elbow Surg.* 2001 May-Jun;10(3):217-24.

5. **Deutsch A, Abboud JA, Kelly J, et al.** Clinical results of revi- sion shoulder arthroplasty for glenoid component loosening. *J Shoulder Elbow Surg.* 2007 Nov-Dec;16(6):706-16.

6. **Elhassan B, Ozbaydar M, Higgins LD, Warner JJP.** Glenoid reconstruction in revision shoulder arthroplasty. *Clin Orthop Relat Res.* 2008 Mar;466(3):599-607.

7. **Barrett WP, Franklin JL, Jackins SE, et al.** Total shoulder arthroplasty. *J Bone Joint Surg Am.* 1987 Jul;69(6):865-72.

8. **Hill JM, Norris TR.** Long-term results of total shoulder arthroplasty following bone grafting of the glenoid. *J Bone Joint Surg Am.* 2001 Jun;83(6):877-83.

9. **Neer CS, Watson KC, Stanton FJ.** Recent experience in total shoulder replacement. *J Bone Joint Surg Am.* 1982 Mar;64(3):319-37.

10. **Sperling JW, Cofield RH, Rowland CM.** Minimum 15- year follow-up of Neer hemiarthroplasty and total shoulder arthroplasty in patients aged fifty years or younger. *J Shoulder Elbow Surg.* 2004 Nov-Dec;13(6):604-13.

11. **Throckmorton TW, Zarkadas PC, Sperling JW, Cofield RH.** Pegged versus keeled glenoid components in total shoulder arthroplasty. *J Shoulder Elbow Surg.* 2010 Jul;19(5):726-33.

12. **Torchia ME, Cofi ld RH, Settergren CR.** Total Shoulder Arthroplasty with the Neer prosthesis: long-term results. *J Shoulder Elbow Surg.* 1997 Nov;6(6):495-505.

13. **Wallace AL, Phillips RL, MacDougal GA, et al.** Resurfacing of the glenoid in total shoulder arthroplasty. J Bone Joint Surg Am. 1999 Apr; 81(4):510-18.

14. **Vavken P, Sadoghi P, von Keudell A, et al.** Rates of radio- lucency and loosening after total shoulder arthroplasty with pegged of keeled glenoid components. *J Bone Joint Surg Am.* 2013 Feb 6;95(3):215-21. http://dx.doi.org/10.2106/ JBJS.L.00286.

15. **Brems J.** The glenoid component in total shoulder arthroplasty. *J Shoulder Elbow Surg.* 1993 Jan;2(1):47-54.

16. **Fox TJ, Cil A, Sperling JW, et al.** Survival of the glenoid component in shoulder arthroplasty. J *Shoulder Elbow Surg.* 2009 Nov-Dec;18(6):859-63.

17. **Martin SD, Zurakowski D, Thornhill TS.** Uncemented glenoid component in total shoulder arthroplasty. *J Bone Joint Surg Am.* 2005 Jun;87(6):1284-92.

18. **Abboud JA, Anakwenze OA, Hsu JE.** Soft-tissue management in revision total shoulder arthroplasty. *J Am Acad Orthop Surg.* 2013 Jan;21(1):23-31.

19. **Riboh JC, Garrigues GE.** Bone grafting in shoulder arthro- plasty. *Othopedics.* 2012 Nov;35(11):966-73.

20. **Bonnevialle N, Melis B, Neyton L, et al.** Aseptic glenoid loosening or failure in total shoulder arthroplasty: revision with glenoid reimplantation. *J Shoulder Elbow Surg.* 2013 Jun;22(6):745-51.

21. **Scalise JJ, Iannotti JP.** Bone grafting severe glenoid defects in revision shoulder arthroplasty. *Clin Orthop Relat Res.* 2008 Jan;466(1):139-45.

22. **Young AA, Walch G.** Fixation of the glenoid component in total shoulder arthroplasty: what is "modern cementing tech- niques?" *J Shoulder Elbow Surg.* 2010 Dec;19(8):1129-36.

23. **Gillespie R, Lyons R, Lazarus M.** Eccentric reaming in total shoulder arthroplasty: a cadaveric study. *Orthopedics.* 2009 Jan;32(1):21.

24. **Iannotti JP, Greeson C, Downing D, et al.** Effect of glenoid de- formity on glenoid component placement in primary shoulder arthroplasty. *J Shoulder Elbow Surg.* 2012 Jan;21(1):48-55.

25. **Iannotti JP, Lappin KE, Klotz CL, et al.** Lift-off resistance of augmented glenoid components during cyclic fatigue load- ing the posterior-superior direction. *J Shoulder Elbow Surg.* 2013 Mar 22. pii: S1058-2746(13)00041-4. doi: 10.1016/j. jse.2013.01.018. [Epub ahead of print]

26. **Kirane YM, Lewis GS, Sharkey NA, Armstrong AD.** Me- chanical characteristics of a novel posterior-step prosthesis for biconcave glenoid defects. *J Shoulder Elbow Surg.* 2012 Jan;21(1):105-15. doi:10.1016/j. jse.2010.12.008.

27. **Rice RS, Sperling JW, Miletti J, et al.** Augmented glenoid component for bone deficiency in shoulder arthroplasty. *Clin Orthop Relat Res.* 2008 Mar;466(3):579-83. doi:10.1007/ s11999-007-0104-4.

28. **Youderian AR, Napolitano LA, Davidson IU, Iannotti JJP.** Management of glenoid bone loss with the use of a new augmented all-polyethylene glenoid component. *Tech Should Surg.* 2012 Dec;13:163-9.

29. **Roche C, et al.** Computer assessment of scapula cortical and cancellous bone removal when correcting a posterior defect using 3 different glenoid prosthesis designs. Transactions of the 59th Annual ORS Meeting. San Antonio, Texas, January 26-29, 2013.

30. **Cheung EV, Sperling JW, Cofield RH.** Revision shoulder arthroplasty for glenoid component loosening. *J Shoulder Elbow Surg.* 2008 May-Jun;17(3):371-5.

31. **Williams GR, Iannotti JJP.** Options for glenoid bone loss: composites of prosthesis and biologics. *J Shoulder Elbow Surg.* 2007 Sep-Oct;16(5 Suppl):267S-72. doi: 10.1016/j. jse.2007.05.003.

32. **Valenti PH, Valle P, Sauzieres PH.** How to revise a PE gle- noid loosening in TSA? Presented at the Paris International Shoulder Course, 2013

33. **Cheung EV, Sperling JW, Cofi ld RH.** Reimplantation of a gle- noid component following component removal and allogeneic bone-grafting. *J Bone Joint Surg Am.* 2007 Aug;89(8):1777- 83.

34. **Phipatanakul WP, Norris TR.** Treatment of glenoid loosening and bone loss due to osteolysis with glenoid bone grafting. *J Shoulder Elbow Surg.* 2006 Jan-Feb;15(1):84-7.

35. **Antuna SA, Sperling JW, Cofield RH.** Reimplantation of a glenoid component after component removal and allograft bone grafting: A report of 3 cases. *J Shoulder Elbow Surg.* 2002 Nov-Dec;11(6):637-41.

36. **Boileau P, Watkinson D, Hatzidakis AM, Hovorka I.** Neer award 2005: The Grammont reverse shoulder prosthe- sis: Results in cuff tear arthritis, fracture sequelae, and revision arthroplasty. *J Shoulder Elbow Surg.* 2006 Sep- Oct;15(5):527-40.

37. **Guery J, Favard L, Sirveaux F, et al.** Reverse total shoulder arthroplasty. *J Bone Joint Surg Am.* 2006 Aug;88(8):1742-7.

38. **Wall B, Nové-Josserand L, O'Connor DP, et al.** Reverse total shoulder arthroplasty: A review of results according to etiol- ogy. *J Bone Joint Surg Am.* 2007 Jul;89(7):1476-85.

39. **Melis B, Bonnevialle N, Neyton L, et al.** Glenoid loosening and failure in anatomical total shoulder arthroplasty: is revi- sion with a reverse shoulder arthroplasty a reliable option? *J Shoulder Elbow Surg.* 2012 Mar;21(3):342-9. doi:10.1016/j. jse.2011.05.021.

40. **Field LD, Dines DM, Zabinski SJ, Warren RF.** Hemiarthro- plasty of the shoulder for rotator cuff arthropathy. *J Shoulder Elbow Surg.* 1997 Jan-Feb;6(1):18-23.

41. **Norris TR, Kelly JD, Humphrey CS.** Management of glenoid bone defects in revision shoulder arthroplasty: A new applica- tion of the reverse total shoulder prosthesis. *Tech Shoulder Elbow Surg.* 2007;8(1):37-46.

42. **Patel DN, Young B, Onyekwelu I, et al.** Reverse total shoul- der arthroplasty for failed shoulder arthroplasty. *J Shoulder Elbow Surg.* 2012 Nov;21(11):1479-83. doi:10.1016/j. jse.2011.11.004.

43. **Roche CP, Stroud NJ, Martin BL, et al.** Achieving fixation in glenoids with superior wear using reverse shoulder arthro- splasty. *J Shoulder Elbow Surg.* 2013 May 7. pii: S1058- 2746(13)00154-7. doi: 10.1016/j. jse.2013.03.008. [Epub ahead of print]

44. **Boileau P, Melis B, Bonnevialle N, et al.** Addressing glenoid loosening or failures in total shoulder arthroplasty. Shoulder Concepts. 2012:181-6.

45. **Hettrich CM, Weldon III E, Boorman RS, et al.** Preoperative factors associated with improvements in shoulder function after humeral hemiarthroplasty. *J Bone Joint Surg Am.* 2004 Jul;86A(7):1446-51.

46. **Levine WN, Djurasovic M, Glasson JM, et al.** Hemiarthro- plasty for glenohumeral osteoarthritis: Results correlated to degree of glenoid wear. *J Shoulder Elbow Surg.* 1997 Sep- Oct;6(5):449-54.

47. **Neyton L, Walch G, Nové-Josserand L, Edwards TB.** Glenoid corticocancellous bone grafting after glenoid component removal in the treatment of glenoid loosening. *J Shoulder Elbow Surg.* 2006 Mar-Apr;15(2):173-9.

48. **Matsen III FA, Bicknell RT, Lippitt SB.** Shoulder arthroplasty: The socket perspective. *J Shoulder Elbow Surg.* 2007 Sep- Oct;16(5 Suppl):S241-7. Epub 2007 Apr 19.

49. **Lynch JR, Franta AK, Montgomery Jr WH, et al.** Self-assessed outcome at two to four years after shoulder hemiarthroplasty with concentric glenoid reaming. *J Bone Joint Surg Am.* 2007 Jun;89(6):1284-92.

50. **Gilmer BB, Comstock BA, Jette JL, et al.** The prognosis for improvement in comfort and function after the ream-and-run arthroplasty for glenohumeral arthritis. *J Bone Joint Surg Am.* 2012 Jul 18;94(14):e102. doi: 10.2106/JBJS.K.00486.

PERIPROSTHETIC INFECTION WITH A FOCUS ON THE KNEE: PATHOGENESIS, EVALUATION, AND TREATMENT

Daniel C. Allison MD, MBA, FACS
Cedars-Sinai Medical Center

Infected revisions result in a hospital length of stay 1.7 times longer than their aseptic counterparts.[10]

www.exac.com/courses
April 8-9 | Advanced Surgical Solutions for Shoulder, Hip and Knee Arthroplasty **| Washington, DC**

Infection remains a significant problem affecting joint implants, with a 1.1-2.2 percent incidence in total hip arthroplasty (THA),[1,2] 0.9-4.0 percent in total knee arthroplasty (TKA)[3,4] and 1-7 percent in all joint arthroplasty.[5] Furthermore, the incidence and prevalence is increasing, with a two-fold increase in hip and knee periprosthetic infections (PPI) from 1990 to 2004.[6,7,8]

The clinical impact is significant, with PPI representing a significant cause of mortality (2.7-18 percent)[9] and the leading cause of primary knee and revision hip arthroplasty failure.[5,4] Infected revisions result in a hospital length of stay 1.7 times longer than their aseptic counterparts.[10] The economic costs are also great, with infected joint replacements costing three to four times that of aseptic primary arthroplasty,[7,11,12] at an estimated cost of $50,000 per infection.[5]

The pathogenesis of PPI involves introduction of the offending organism and subsequent establishment and development of infection. Introduction of the organism can occur through three means: 1) direct inoculation – which is estimated as the cause of 60 percent of PPI;[13] 2) hematogenous spread – 34 percent of cases of S. Aureus bacteremia result in PPI;[13] 3) contiguous spread from adjacent focus (i.e. surgical site infection) – 41 percent of PPI cases in one study resulted from adjacent surgical site infection.[14] The establishment and development of infection is related to host factors (local and systemic immunosuppression), pathogen factors (virulence, susceptibility to host and medical defenses, bacterial load), and outside factors (bacterial contamination and environment). A multitude of host factors have a significant impact of the development of PPI, including: obesity, smoking, myocardial infarction, atrial fibrillation, rheumatologic disease, diabetes, public assistance, organ transplantation, coagulopathy, medical comorbidities (Charlson index > 1 and ASA > 2), systemic malignancy, malnutrition (five

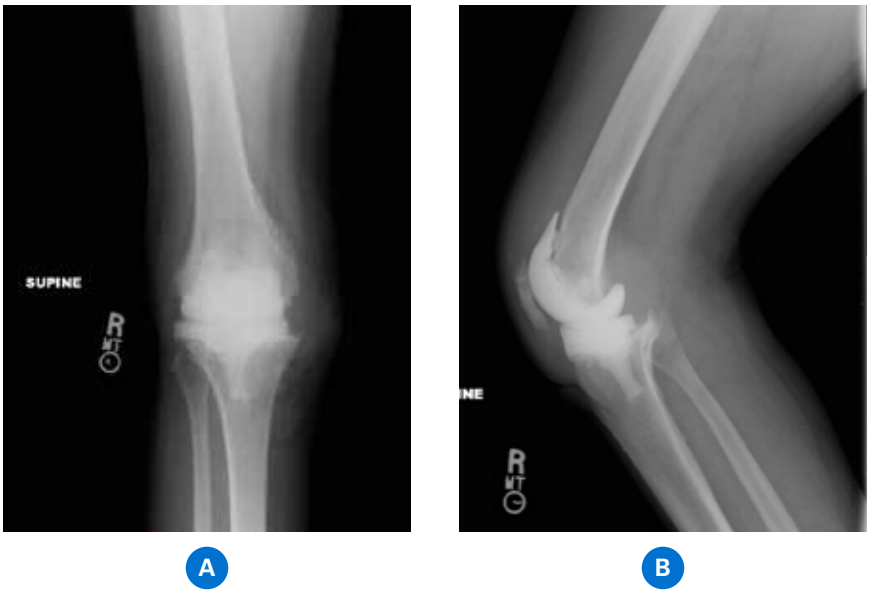

Figure 1A and 1B. After articulating antibiotic spacer placement in treatment of chronic TKA infection.

to seven times increased major wound complications), and anemia.[9,15] Biofilm formation remains the key component in the development of infection, and is related to host, pathogen, and environmental factors. Biofilm is defined as the aggregation of microbe colonies enclosed within an extracellular polysaccharide matrix (glycocalyx) that adheres to the surface of implants or devitalized bone. Biofilm protects the organism from antibiotics and host defense mechanisms, such as antibody formation and phagocytosis, allowing infections to exist in a subclinical state and recur. One study indicates that 59 percent of orthopaedic biomaterial-related infections have positive findings of glycocalyx-enclosed organisms on electron microscopy.[13]

The diagnosis of PPI can be challenging and recent guidelines have significantly helped our ability to diagnose this often elusive condition.[16] Musculoskeletal Infection Society (MSIS) criteria for diagnosis include one of the following:

- A sinus tract communicating with the prosthesis; or
- A pathogen is isolated by culture from two separate tissue or fluid samples obtained from the affected prosthetic joint

Or four of the six following:

- Elevated ESR or CRP
- Elevated synovial white blood cell (WBC) count (as low as 1,100 – 4,000)
- Elevated synovial neutrophil percent (as low as 64-69 percent PMN)
- Presence of purulence in the affected joint
- Isolation of a microorganism in one culture of periprosthetic tissue or fluid
- Greater than five neutrophils per high-power field in five high-power fields observed from histologic analysis of periprosthetic tissue at 400 times magnification

The prevention of PPI mirrors the same approach we use to treat the condition. The primary goals involve 1) optimizing systemic host immune and healing potential, 2) eradicating potential sources of hemotogenous bacterial innoculation, 3) optimizing the local soft tissue envelope, and 4) minimizing local contamination. In regard to optimizing host immune and healing potential, the surgeon should ensure strict smoking cessation, strict glycemic control, nutritional optimization (even in the morbidly obese), maintenance of total lymphocyte count (ALC >1500) and prealbumin (>3.5 g/dl) in high risk patients, oral vitamin and mineral supplementation [Zinc (>5 mcg/ml) and Transferrin (>200 ng/ml)], weight loss, cessation of immunosuppressive medications (especially biologic rheumatologic agents), correction of anemia and coagulopathies, optimization of medical comorbidities (cardiac, pulmonary, etc.), and avoidance of pre-surgical hospital stay.[17,18,19,20] The elimination of sources of bacterial seeding includes confirming the absence of active dental,

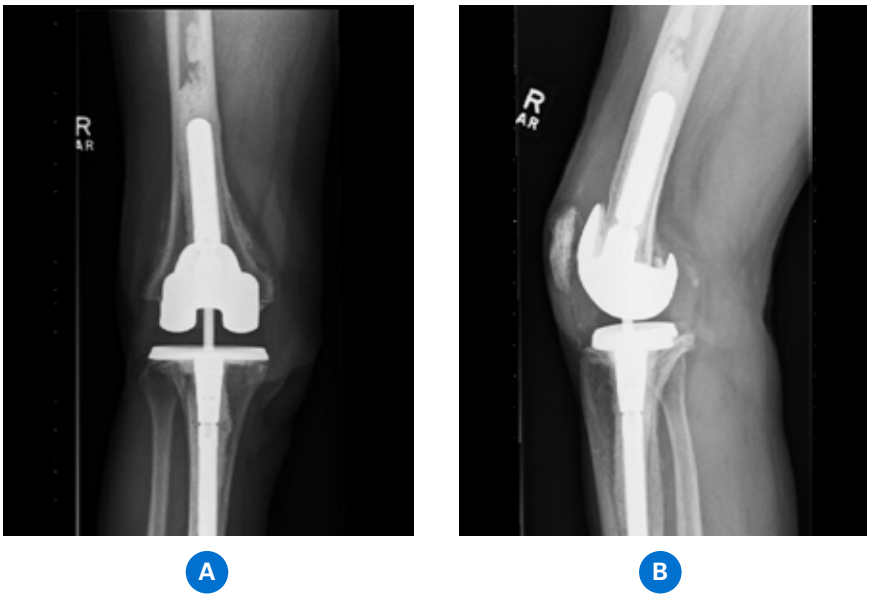

Figure 2A and 2B. Two years after reimplantation, with no evidence of infection.

urinary tract, skin, and gastrointestinal tract infections. Optimization of the local soft tissue envelope involves treatment of vascular insufficiencies (arterial & venous), and the careful planning of surgical approaches, avoiding unnecessary and superficial skin flaps, and using local rotational flaps when appropriate. Local contamination can be minimized through meticulous skin care (psoriasis, breakdown, ulcers), MRSA testing in high risk patients (institutionalized), mupirocin x one week in MRSA carriers, chlorhexidene shower starting one to five days prior to surgery, preoperative chlorhexidine wipes on the day of surgery, and shaving the surgical site with clippers.[22,23,24]

Despite our best efforts at prevention, periprosthetic joint infections still occur. The goals of treatment of these infections must include: 1) a thorough and meticulous removal and debridement of all infected and devitalized bone, soft tissue, and foreign material, 2) maintenance of mechanical stability, 3) preservation of the soft tissue envelope, and 4) delivery of appropriate antibiotic, locally and systemically. In my experience, persistent refractory PPI is usually secondary to one or more of these issues not being addressed. The treatment options for periprosthetic infection of the knee include:

- Chronic antibiotic suppression alone
- Irrigation & debridement (I&D) and retention of prosthesis with or without modular component exchange
- Single staged implant removal & immediate reimplantation
- Two staged implant removal & reimplantation
- Using a temporary spacer (static antibiotic cement, articulating antibiotic cement, or metal / polyethlene prosthetic secured with antibiotic cement)
- Implant removal & knee arthrodesis
- Above knee amputation

With regard to antibiotic suppression alone, success rates are low, and this treatment is usually only considered in the very sick or elderly.[25] Surgical I&D with component retention also has variable success rates (18-52 percent), especially in the chronic setting, which may be improved with antibiotic suppression.[26,27]

Single staged implant removal and reimplantation has recently emerged as a viable option in chronic PPI cases. One study comparing single staged revision to standard two staged revision demonstrated a non-statistical lower infection rate in the single staged group (0 percent vs 7 percent [$P = 0.16$]) and statistically improved Knee Society Scores in the single staged group (88 vs 76 [$P < 0.001$]); however, the single staged cohort was carefully selected.[28]

With regard to end-stage procedures, above knee amputation remains a procedure of last resort, with significant increases in energy expenditure for ambulation (68 percent increase in metabolic demand compared to normal limb), which may be particularly problematic in the elderly or those with medical comorbidities. Knee arthrodesis carries the advantages of a significant cure rate, a longevious and durable construct, and improved ambulatory ability when compared to above knee amputation in elderly,[29]

with the disadvantages of poor acceptance from the patient and difficulty converting to secondary total knee arthroplasty.

Many argue that two-staged implant removal and reimplantation remains the gold standard treatment of chronic PPI of the knee.[25] This method of treatment involves implant removal, meticulous debridement, complete synovectomy, and insertion of a mechanical construct which serves to maintain the space for future reimplantation, a means to deliver antibiotic locally, and means to confer stability to the area. This "spacer" may consist of a static block of antibiotic cement or an articulating construct similar to that of a total knee arthroplasty. After implant removal and antibiotic pacer placement, a prolonged course of tailored intravenous antibiotics is instituted, with planned reimplantation at eight-24 weeks (if and when clinical, serologic, and aspiration studies show no evidence of infection). The goals of antibiotic spacer use include: 1) maintenance of joint stability, 2) elution of local antibiotic, 3) optimization of patient function and comfort, and 4) increasing the ease of revision surgery by preserving bone stock, maintaining the appropriate space, and preventing soft tissue contracture.

Articulating antibiotic spacers offer potential benefits of improved antibiotic delivery and increased surface area for greater antibiotic elution.

Static block spacers demonstrate 80-90+ percent cure rates, with the downsides of soft tissue contracture, instability / patient discomfort, posterior femoral condyle soft tissue growth, quadriceps scarring to anterior distal femur, and bone loss[30]. Metal and polyethylene "spacers" have evolved in order to avoid the downsides of static spacers, but serve as persistent source of biofilm establishment; early results demonstrate similar reinfection rates and improved range of motion with articulating metal and polyethylene construct (107.8° vs 93.7°), however, long term results are still pending.[31]

Articulating antibiotic spacers offer potential benefits of improved antibiotic delivery and increased surface area for greater antibiotic elution. They also optimize revision surgery by potentially preserving motion, prevention of soft tissue contracture, and preservation of the joint space, especially in the area posterior femoral condyles and anterior femur. Many articles have been published comparing static and articulating spacers, and a well-written review summarizes seven of the best studies, noting a similar reinfection rate between both (7 percent articulating vs 12 percent Static [P = 0.2]), similar functional scores between both, and improved range of motion with articulating spacers 101° (articulating) vs 91° (static) (P = 0.0002).[32]

In summary, periprosthetic joint infections remain a major problem in the arthroplasty world, with increasing incidence and prevalence, high associated morbidity and mortality, and extensive monetary burden. Preoperative prevention involves optimizing medical comorbidities, eradicating potential sources of bacteremia, optimizing the soft tissue envelope, and decreasing local bacterial contamination. Effective treatment requires adequate debridement, ensuring appropriate soft tissue coverage, conference of stability to the area, and delivering appropriate antibiotic therapy. The two-staged procedure remains the gold standard for chronic PPI, and articulating antibiotic spacers optimize the goals of infection treatment as well as joint preparation for implantation. •

REFERENCES

1. **Urquhart DM, Hanna FS, Brennan SL, Wluka AE, Leder K, Cameron PA, Graves SE, Cicuttini FM.** Incidence and risk factors for deep surgical site infection after primary total hip arthroplasty: a systematic review. *J Arthroplasty.* 2010 Dec;25(8):1216-22.

2. **Ong KL, Kurtz SM, Lau E, Bozic KJ, Berry DJ, Parvizi J.** Prosthetic joint infection risk after total hip arthroplasty in the Medicare population. *J Arthroplasty.* 2009 Sep;24(6 Suppl):105-9.

3. **Jämsen E, Huotari K, Huhtala H, Nevalainen J, Konttinen YT.** Low rate of infected knee replacements in a nationwide series--is it an underestimate? *Acta Orthop.* 2009 Apr;80(2):205-12.

4. **Adeli B, Parvizi J.** Strategies for the prevention of periprosthetic joint infection. J *Bone Joint Surg* Br. 2012 Nov;94(11 Suppl A):42-6.

5. **Illingworth KD, Mihalko WM, Parvizi J, Sculco T, McArthur B, el Bitar Y, Saleh KJ.** How to minimize infection and thereby maximize patient outcomes in total joint arthroplasty: a multicenter approach: AAOS exhibit selection. J Bone Joint Surg Am. 2013 Apr 17;95(8):e50.

6. **Kurtz S, Ong K, Lau E, Mowat F, Halpern M.** Projections of primary and revision hip and knee arthroplasty in the United States from 2005 to 2030. *J Bone Joint Surg Am.* 2007 Apr;89(4):780-5.

7. **Kurtz SM, Lau E, Schmier J, Ong KL, Zhao K, Parvizi J**. Infection burden for hip and knee arthroplasty in the United States. *J Arthroplasty.* 2008 Oct;23(7):984-91.

8. **Kurtz SM, Ong KL, Schmier J, Zhao K, Mowat F, Lau E.** Primary and revision arthroplasty surgery caseloads in the United States from 1990 to 2004. *J Arthroplasty.* 2009 Feb;24(2):195-203.

9. **Matar WY, Jafari SM, Restrepo C, Austin M, Purtill JJ, Parvizi J.** Preventing infection in total joint arthroplasty. *J Bone Joint Surg Am.* 2010 Dec;92 Suppl 2:36-46.

10. Nationwide Inpatient Sample: 1990 – 2003.

11. **Bozic KJ, Kurtz SM, Lau E, Ong K, Chiu V, Vail TP, Rubash HE, Berry DJ.** The epidemiology of revision total knee arthroplasty in the United States. Clin Orthop Relat Res. 2010 Jan;468(1):45-51.

12. **Bozic KJ, Kurtz SM, Lau E, Ong K, Vail TP, Berry DJ.** The epidemiology of revision total hip arthroplasty in the United States. J Bone Joint Surg Am. 2009 Jan;91(1):128-33.

13. **Cierny, G, McLaren A, Wongworarat M.** Orthopedic Knowledge Update: Musculoskeletal Infection. American Academy of Orthopedic Surgeons, Rosemont, Il. 2009.

14. **Phillips JE, Crane TP, Noy M, Elliott TS, Grimer RJ.** The incidence of deep prosthetic infections in a specialist orthopaedic hospital: a 15-year prospective survey. *J Bone Joint Surg Br.* 2006 Jul;88(7):943-8.

15. **Bozic KJ, Lau E, Kurtz S, Ong K, Berry DJ.** Patient-related risk factors for postoperative mortality and periprosthetic joint infection in medicare patients undergoing TKA. *Clin Orthop Relat Res.* 2012 Jan;470(1):130-7.

16. **Parvizi J, Zmistowski B, Berbari EF, et al.** New Definition for Periprosthetic Joint Infection: From the Workgroup of the Musculoskeletal Infection Society. *Clinical Orthopaedics and Related Research.* 2011;469(11):2992-2994.

17. **Marchant MH Jr, Viens NA, Cook C, Vail TP, Bolognesi MP.** The impact of glycemic control and diabetes mellitus on perioperative outcomes after total joint arthroplasty. *J Bone Joint Surg Am.* 2009 Jul;91(7):1621-9.

18. **Mraovic B, Suh D, Jacovides C, Parvizi J.** Perioperative hyperglycemia and postoperative infection after lower limb arthroplasty. *J Diabetes Sci Technol.*2011 Mar 1;5(2):412-8.

19. **Shahi A, Parvizi J.** Prevention of Periprosthetic Joint Infection. *Arch Bone Jt Surg.* 2015 Apr;3(2):72-81.

20. **Garvin KL, Konigsberg BS.** Infection following total knee arthroplasty: prevention and management. *Instr Course Lect.* 2012;61:411-9.

21. **Dunbar MJ, Richardson G.** Minimizing infection risk: fortune favors the prepared mind. *Orthopedics.* 2011 Sep 9;34(9):e467-9.

22. **Hacek DM, Robb WJ, Paule SM, Kudrna JC, Stamos VP, Peterson LR.** Staphylococcus aureus nasal decolonization in joint replacement surgery reduces infection. *Clin Orthop Relat Res.* 2008 Jun;466(6):1349-55.

23. **Rao N, Cannella BA, Crossett LS, Yates AJ Jr, McGough RL 3rd, Hamilton CW.** Preoperative screening/decolonization for Staphylococcus aureus to prevent orthopedic surgical site infection: prospective cohort study with 2-year follow-up. *J Arthroplasty.* 2011 Dec;26(8):1501-7.

24. **Lamplot JD, Luther G, Mawdsley EL, Luu HH, Manning D.** Modified Protocol Decreases Surgical Site Infections after Total Knee Arthroplasty. *J Knee Surg.*2015 Oct;28(5):395-403.

25. **Parvizi J, Zmistowski B, Adeli B.** Periprosthetic joint infection: treatment options. *Orthopedics. 2010* Sep 7;33(9):659.

26. **Choi HR, von Knoch F, Zurakowski D, Nelson SB, Malchau H.** Can implant retention be recommended for treatment of infected TKA? *Clin Orthop Relat Res.* 2011 Apr;469(4):961-9.

27. **Deirmengian C, Greenbaum J, Lotke PA, Booth RE Jr, Lonner JH.** Limited success with open debridement and retention of components in the treatment of acute Staphylococcus aureus infections after total knee arthroplasty. *J Arthroplasty.* 2003 Oct;18(7 Suppl 1):22-6.

28. **Haddad FS, Sukeik M, Alazzawi S.** Is single-stage revision according to a strict protocol effective in treatment of chronic knee arthroplasty infections? *Clin Orthop Relat Res.* 2015 Jan;473(1):8-14.

29. **Chen AF, Kinback NC, Heyl AE, McClain EJ, Klatt BA.** Better function for fusions versus above-the-knee amputations for recurrent periprosthetic knee infection. *Clin Orthop Relat Res.* 2012 Oct;470(10):2737-45.

30. **Leone JM, Hanssen AD.** Management of infection at the site of a total knee arthroplasty. *Instr Course Lect.* 2006;55:449-61.

31. **Emerson RH Jr, Muncie M, Tarbox TR, Higgins LL.** Comparison of a static with a mobile spacer in total knee infection. *Clin Orthop Relat Res.* 2002 Nov;(404):132-8.

32. **Voleti PB, Baldwin KD, Lee GC.** Use of static or articulating spacers for infection following total knee arthroplasty: a systematic literature review. *J Bone Joint Surg Am.* 2013 Sep 4;95(17):1594-9.

EVALUATION AND TREATMENT OF THE INFECTED SHOULDER ARTHROPLASTY

Daniel J. Hackett, Jr, MD
Georgia Regents Medical Center

Lynn A. Crosby, MD
Georgia Regents Medical Center

www.exac.com/courses
February 12-13 | Advanced Surgical Solutions for Shoulder, Hip and Knee Arthroplasty **| Miami, Fla.**

Infection following shoulder arthroplasty, although infrequent, remains one of the most common postoperative complications encountered and accounts for a large number of failures in both primary and revision shoulder a throplasty.[1-5] The increase in the number of primary shoulder arthroplasties being performed has increased the number of patients requiring revision arthroplasty for the treatment of infection. Infection poses a number of issues for the surgeon with respect to diagnosis, treatment, and revision following eradication of infection. Diagnosis of infection relies upon a high clinical suspicion and appropriate diagnostic studies.[1] Due to the low virulence of organisms, such as *Propionibacterium acnes (P. acnes)*, it is our opinion that postoperative pain following shoulder arthroplasty should be considered due to infection, until proven otherwise.[1,6-7] There has yet to be a consensus on the optimal treatment for periprosthetic infection after shoulder arthroplasty, and most treatment is based upon surgeons' past clinical experiences and use of data from infection treatment following hip and knee arthroplasty. The hip and knee literature provide some insight for infection treatment. However, the common infective organisms, the presenting signs and symptoms, laboratory data, and clinical course all prove to be somewhat different in shoulder arthroplasty.[8] More studies related to infection following shoulder arthroplasty are published each year; however, these studies have smaller numbers and lack the power analysis that is found in the hip and knee literature.[8] Most agree that treatment should involve diagnosis of the infective organism, an adequate debridement followed by one- or two-stage revision, and species specific IV antibiotic treatment following the initial operation.[5,7,9-20] In most cases, elimination of infection requires aggressive debridement of soft tissues, which creates yet another reconstructive problem for the surgeon.[21] Debridement creates a larger amount of dead space, providing organisms an opportunity for re-infection. Aggressive soft tissue debridement may also eliminate the amount of soft tissue needed to provide stability and function when considering revision arthroplasty options.[10,20-24] Results of revision arthroplasty following infection have also differed in terms of pain improvement, rate of complications, and functional status.[5,7,9-20] This review will focus on what we currently understand about revision shoulder arthroplasty with a focus on the results of two-stage revision with anatomic and reverse total shoulder arthroplasty.

Type of Infection	Time Period of Infection	Treatment
Type I	Positive cultures at time of revision	Organism specific antibiotic treatment with close observation
Type II	Acute infection within 30 days of surgery	Surgical debridement with retention of prosthesis
Type III	Acute hematogenous infection > 30 days after surgery	Surgical debridement with retention of implant or two-stage treatment with antibiotic spacer
Type IV	Chronic infection	Surgical debridement with implant removal, temporary antibioic spacer placement, and delayed reimplantation

Table 1. Classification and Treatment Options for Periprosthetic Infections

PATIENT EVALUATION

Infection should be ruled out in any patient with a painful shoulder arthroplasty.[1,6-7] A complete history should be taken, with particular attention to the time since the initial operation, constitutional symptoms, recent hematogenous infections, and recent dental work or other procedures. The patient should be questioned about recent use of oral antibiotics, anti-inflammatory medication, and narcotics, as these may mask symptoms and interfere with prompt diagnosis. Multiple factors can increase the risk of infection including systemic factors, such as malnutrition, diabetes mellitus, chronic hypoxia, obesity, renal or liver failure, intravenous drug use, and immunodeficency.[24-27] Limb specific risk factors include previous shoulder surgery, local corticosteroid injections, chronic lymphedema, venous stasis, vascular compromise, and radiation fibrosis.[7,24,28,29] Other risk factors for periprosthetic infection include postoperative hematoma formation, revision surgery, intial surgery performed for fracture, cuff tear arthropathy, malignancy, or radiation-induced osteonecrosis.[7]

Physical signs of periprosthetic infection can often be very subtle. Infections are often indolent, especially those involving *P. acnes*, in which pain may be the only presenting symptom.[1,6-7] Worsening results of the physical exam, such as a decreasing range of motion, should warrant further work up for infection.[1,6-7] Obvious signs of infection, such as fever, chills, and certainly drainage and sinus tract formation, obviously warrant further work up.

DIAGNOSTIC WORKUP, IMAGING, AND EVALUATION

The diagnostic workup should include standard shoulder radiographs. The laboratory evaluation should include a complete blood count (CBC) with differential, erythrocyte sedimentation rate (ESR), and C-reactive protein (CRP).[7,24,28,30] With early infection, radiographs will usually appear normal. With subacute or late infection, periprosthetic osteopenia or osteolysis might be evident, as well as pseudo-subluxation of the humeral head component.[31] Diagnostic radiographic studies, such as MRI and ultrasonography, can be helpful in detecting surrounding osteomyelitis and loculated abscesses but are not routinely utilized. Other studies, which are not routinely obtained, include technetium Tc-99 bone scans and indium -111-labeled white blood cell scintigraphy as the sensitivity and specifics of these tests make interpretation of the results difficult.[7,9,29] The peripheral leukocyte count is usually within normal range, as is the neutrophil cell distribution. However, if either is elevated, it can be helpful. Patient history should be taken into consideration when evaluating the ESR and CRP, as these are non-specific markers of inflammation and can be normally elevated in the perioperative period. The ESR and CRP are often not elevated in cases of *P. acnes* infection.[10] In all cases where there is high clinical suspicion for deep infection, aspiration of the glenohumeral joint should be performed. Synovial fluid analysis should include cell count with differential; gram stain; and cultures for aerobes, anaerobes, fungi, and mycobacteria.[25] Aerobic and anaerobic incubation periods should be specified to the laboratory, as *P. acnes* can take up to three to four weeks for positive cultures.[1] The gram stain is positive in 75 percent of proven cases of infection; cultures are positive in 80 percent

of cases. A negative gram stain or culture from an aspiration, however, does not rule out infection.[7,15,24,28,29]

MANAGEMENT OF PERIPROSTHETIC INFECTION

Management of periprosthetic infection should take into account multiple factors including timing of infection (acute, subacute, or late), infecting organism(s), overall health of the patient, soft tissue and bony integrity, and patient age and expectations. Ideal management involves successful elimination of infection while minimizing functional compromise and the incidence of complications. In patients with medical comorbidities that may prevent or limit operative management, species directed long-term suppressive antibiotic therapy may be required.

Table 1 depicts the classification and treatment recommendations for periprosthetic infections. In acute infections (less than four weeks), a thorough irrigation and debridement with polyethylene exchange (if possible) is appropriate.[32-33] There is little data available on the outcomes of this approach but removing the polyethylene liner to expose as much surface area as possible for irrigation is the rationale. In infections that present greater than four weeks after the initial operation, complete removal of implants is indicated with the options of resection arthroplasty or revision either in a single or two-staged approach, followed by species directed antibiotic therapy.[5,7,9-20] Patients who are low demand or are not medically appropriate for significant revision operations have shown benefits from placement of an antibiotic impregnated cement spacer or simple resection arthroplasty as their definitive treatment.[10,17,19] Weber and coworkers showed near comparable outcomes with resection arthroplasty versus two-staged revision with reverse total shoulder arthroplasty (rTSA) (Constant scores 32.7 and 40.1, respectively), with the main difference representing differences in range of motion.[19] There has been some success with single-stage revisions. Ince and associates reported on nine patients who underwent a one-stage revision without recurrent infection, and Klatte and colleagues reported eradication in 33 of 35 patients.[11,12]

However, most studies of one-staged revision have reported high reinfection rates. There are more studies reporting successful elimination of infection and better functional results with a two-staged procedure. One-staged procedures have the potential for better functional results and are more cost effective but have a higher risk for re-infection, which is primarily secondary to not having the organism identified prior to the reimplantation.[19]

In medically stable patients with relatively high demand, the two-staged exchange is generally accepted as the treatment of choice.[10,13,14,19,20] In a two-staged revision, antibiotics should be held until intraoperative cultures are obtained. Broad spectrum intravenous antibiotics can then be initiated, followed by placement of an antibiotic impregnated cement spacer. Placement of a prefabricated spacer has shown parallel results to those spacers made intraoperatively.[10] Figure 1 shows a radiograph and an example of a prefabricated antibiotic spacer. Use of these prefabricated spacers reduces operative time and provides a more anatomic humeral head component, which can reduce glenoid wear; it is required to remain in place for long periods.[10] Prefabricated antibiotic spacers elute antibiotic over a longer period of time, as they have a large surface area.[10] Postoperatively, antibiotics are generally continued for six to eight weeks. Laboratory markers, such as CRP and ESR, as well as Interleukin - 6 (IL-6), have been shown to be reliable indicators to follow serially as markers for eradication of infection.[10] If lab values continue to remain elevated, suspicion for recurrent infection should remain high.[10] A second washout with reinsertion of an antibiotic spacer may be needed if the IL-6 remains high over a long period of time. It has been shown that once the IL-6 has returned to normal a revision procedure can safely be considered.[10] If the ESR and or CRP are used as reimplant markers, the time in between explant and ultimate revision has been shown to be approximately four months.[20] The IL-6 returns to normal much faster than the ESR or the CRP and may allow better functional results if the revision is performed at an earlier time.[10] Indications for not proceeding with a second staged procedure would include poor patient health or patients who are satisfied with the function with the antibiotic impregnated spacer in place.[10,17,19] In a study by Coffey and coworkers, four of 16 patients who were planned for a second staged revision were satisfied with their spacer and deferred removal.[10]

Since the goal of the first stage of the procedure is to eradicate infection, the second stage can be technically demanding for the surgeon, secondary to the loss of significant soft tissue including the rotator cuff musculature.[21] Table 2 displays the results of recent two-stage exchanges. Total infection free rates are about 89 percent. Two studies noted a reinfection rate of

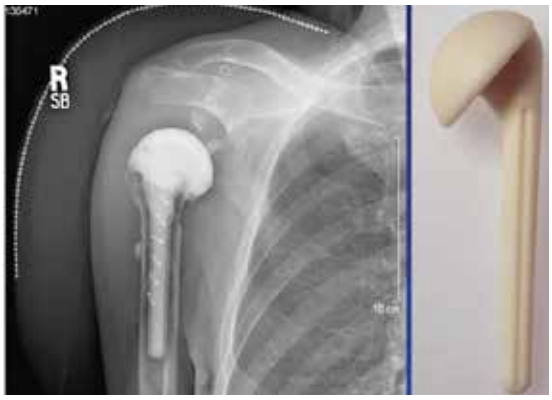

Figure 1. AP radiograph (left) and picture (right) of the InterSpace® Shoulder (Tecres S.p.A.; Verona, Italy).

Study	No. of Patients	Therapy	No. Infection Free (percent)	Constant Score	Neer	Fain Fra	ROM	Complications/ notes
Jawa et al. 2010	15	10 rTSA 5 hemi or aTSA	13 (86.7)			rTSA: 5 moderate 5 severe Hemi/ aTSA 4 mild 1 moderate	FF: rTSA: 74 Hemi/aTSA: 61	3 prostalac fractures 2 recurrent infections with rTSA 1 recurrent infection with hemi/aTSA
Romano et al. 2012	17	13 rTSA 3 hemi 1 aTSA	17 (100)	38	5 excellent 9 satisfactory 3 unsatisfactory		Abd 55, ER 12	5 dislocations/ instability
Weber et al. 2011	4	3 rTSA 1 hemi	4 (100)	40	2 satisfactory 2 unsatisfactory		Abd 62	humerus fracture with radial nerve palsy
Sabesan et al. 2011	17	17 rTSA	16 (94.1)				FF 123, ER 26	5 dislocations/ instability 1 infection cleared with repeat 2-stage revision
Coffey et al. 2010	12	10 rTSA 1 aTSA 1 arthrodesis	12 (100)	57			FF 110, ER 20	
Coste et al. 2004	10	N/A	6 (60)	35				Infection eradicated with further surgery in all
Cuff et al. 2008	12	12 rTSA	12 (100)					1 dislocation 1 periprosthetic fracture with radial nerve palsy
Jerose and Schneppen-heim 2003	8	N/A	8 (100)	48				
Mileti et al. 2004	4	1 aTSA 3 hemi	4 (100)			2 without pain 1 mild 1 moderate	FF 80, ER 50	2-stage revision without prostalac
Sperling et al. 2001	3	N/A	3 (100)				Abd 180, ER 30	2-stage revision without prostalac
Strickland et al. 2008	19	5 aTSA 13 hemi 1 N/A	12 (63.1)		2 excellent 4 satisfactory 13 unsatisfactory		Abd 89, ER 30	1 greater tuberosity fracture 1 hematoma 1 humeral non-union 1 unstable implant
Seitz and Da-macen 2002	8	3 aTSA 5 hemi	8 (100)				Abd 48, ER 55	
Total	**129**	**65 rTSA** **11 aTSA** **5 hemi or aTSA** **25 hemi** **1 arthrodesis** **22 N/A**	**115 (89.1)**					

Table 2. Overview of the Treatment Results of Infected Shoulder Arthroplasties Utilizing Two-stage Revisions

37 and 40 percent; however, an infecting organism was only obtained in a few patients in both of these studies.[7,9] Coste and colleagues noted a suspicion of continued infection in two of the four patients at the time of the second stage revision that eventually required repeat revision.[7] Romano and associates noted a decrease in mean visual analog pain score (VAS) from 6.4 to 1.5 and improvement in mean Constant score from 26 to 38.[3] There were no re-infections, but a complication rate of 15.9 percent was reported.[14] Sabesan and coworkers reported a mean improvement in Penn shoulder scores of 24.9 to 66.4 with a 35 percent complication rate, including one re- infection.[20] Coffey and colleagues found patients to have significant improvement in mean visual analog pain score from 8.4 before spacer placement to 0.5 at first follow up and an increase in Constant score from 16 to 57.[10] Cuff and coworkers reported great improvement in mean abduction from 36° preoperatively to 76° postoperatively, forward flexion from 43° to 80°, and external rotation 10° to 25°.[13] Although Strickland reported a high re-infection rate, patients reported an improvement in pain score and in ROM.[9] As with any revision, the results reported have been inferior compared to those for primary aTSA. Most complications in these studies were related to instability and/or periprosthetic fracture.[14,20] Particular attention should be paid to soft tissue tensioning, as the incidence of dislocation has been reported to be high. Sabesan and associates and Romano and colleagues both reported laxity and or dislocation in five of 17 revisions.[14,20] As adequate debridement of suspicious soft tissue is required in the initial debridement, second-stage revision with rTSA is supported by many investigators since it allows the initial debridements to be performed with less concern for preservation of soft tissues.[10,13,14,19,20] Of the 129 two-stage revisions published, more than half of revisions utilized rTSA as the implant of choice.

CONCLUSION

Periprosthetic infection is one of the complications associated with a high morbidity following shoulder arthroplasty. It poses a great burden to the patient, and a significant technical challenge to the surgeon. With the increasing awareness of *P. acnes*, as the organism responsible for periprosthetic infections, shoulder surgeons have become more concerned with patients who present with a painful shoulder following arthroplasty.[1-5] There is currently a lack of consensus of the criteria required for diagnosing periprosthetic infection; however, studies have shown that both the clinical presentation and the diagnostic evaluation both play a role in early diagnosis.[1,6-7] Identification of the infective organism prior to initial revision surgery is very helpful in eradicating infection. The initial treatment after the diagnosis of periprosthetic infection remains controversial. While some investigators have reported good results with one-stage revisions, more reproducible results have been shown with the two-stage revision. As diagnostic criteria and identification of organisms prior to explant improves, one-stage revisions may show more promise in the future.[19] Irrespective of the revision choice, multiple tissue cultures along with an adequate debridement at time of initial explant are crucial, followed by the need for an interdisciplinary approach utilizing infectious disease consultants.[25] Many patients have shown improved functional results with the use of an antibiotic spacer as the definitive treatment.[10,17,19] The use of commercially produced spacers appears to provide the patient with a better functional overall result compared to those made by the surgeon intraoperatively.[10] The timing of a second-stage revision, by monitoring IL-6 levels may allow earlier implantation and potentially better functional results.[10] As with any shoulder arthroplasty, the integrity of the remaining soft tissues following debridement should direct the implant of choice for revision.[21] Reverse total shoulder arthroplasty, in most cases, appears to be the implant of choice as it provides more stability and greater potential functional results.[10,13,14,19,20] The use of antibiotic impregnated cement is highly recommended when performing the revision procedure.[10] •

Reprinted from The Bulletin of the Hospital for Joint Disease, Volume 71, Supplement 2, 2013, Pages S88-S93, with permission.

REFERENCES

1. **Pottinger P, Butler-Wu S, Neradilek MB, et al.** Prognostic factors for bacterial cultures positive for Propionibacterium acnes and other organisms in a large series of revision shoulder arthroplasties performed for stiffness, pain, or loosening. *J Bone Joint Surg Am.* 2012 Nov 21;94(22):2075-83.

2. **Cofi RH, Edgerton BC.** Total shoulder arthroplasty: compli- cations and revision surgery. *Instr Course Lect.* 1990;39:449- 62.

3. **Fox TJ, Cil A, Sperling JW, et al.** Survival of the glenoid component in shoulder arthroplasty. *J Shoulder Elbow Surg.* 2009 Nov-Dec;18(6):859-63.

4. **Gonzalez JF, Alami GB, Baque F, et al.** Complications of unconstrained shoulder prostheses. *J Shoulder Elbow Surg.* 2011 Jun;20(4):666-82.

5. **Sperling JW, Kozak TK, Hanssen AD, Cofield RH.** Infec- tion after shoulder arthroplasty. *Clin Orthop Relat Res.* 2001 Jan;(382):206-16.

6. **Berthelot P, Carricajo A, Aubert G, et al.** Outbreak of post- operative shoulder arthritis due to Propionibacterium acnes infection in non-debilitated patients. Infect Control Hosp Epidemiol. 2006 Sep;27(9):987-90.

7. **Coste JS, Reig S, Trojani C, et al.** The management of infection in arhtroplasty of the shoulder. *J Bone Joint Surg Br.* 2004 Jan;86(1):65-9.

8. T**oms AD, Davidson D, Masri BA, Duncan CP.** The manage- ment of perioprosthetic infection in total joint arthroplasty. *J Bone Joint Surg Br.* 2006 Feb;88(2):149-55.

9. **Strickland JP, Sperling JW, Cofield RH.** The results of two- stage re-implantation for infected shoulder replacement. *J Bone Joint Surg Br.* 2008 Apr;90(4):460-5.

10. **Coffey MJ, Ely EE, Crosby LA.** Treatment of glenohumeral sepsis with a commercially produced antibiotic-impregnated cement spacer. *J Shoulder Elbow Surg.* 2010 Sep;19(6):868- 73.

11. **Ince A, Seemann K, Frommelt L, et al.** One-stage exchange shoulder arthroplasty for peri-prosthetic infection. *J Bone Joint Surg Br.* 2005 Jun;87(6):814-8.

12. **Klatte TO, Junghans K, Al-Khateeb H, et al.** Single-stage revision for peri-prosthetic shoulder infection. *J Bone Joint Surg Br.* 2013 Mar;95-B(3):391-5.

13. **Cuff DJ, Virani NA, Levy J, et al.** The treatment of deep shoul- der infection and glenohumeral instability with debridement, reverse shoulder arthroplasty and postoperative antibiotics. *J Bone Joint Surg Br.* 2008 Mar;90(3):336-42.

14. **Romano CL, Borens O, Monti L, et al.** What treatment for periprosthetic shoulder infection? Results from a multicentre retrospective series. *Int Orthop.* 2012 May;36(5):1011-7.

15. J**erosch J, Schneppenheim M.** Management of infected shoulder replacement. *Arch Orthop Trauma Surg.* 2003 Jun;123(5):209-14.

16. **Mileti J, Sperling JW, Cofield RH.** Reimplantation of a shoulder arthroplasty after a previous infected arthroplasty. *J Should Elbow Surg.* 2004 Sep-Oct;13(5):528-31.

17. **Jawa A, Shi L, O'Brien T, et al.** Prosthesis of antibiotic-loaded acrylic cement (PROSTALAC) use for the treatment of infec- tion after shoulder arthroplasty. *J Bone Joint Surg Am.* 2011 Nov 2;93(21):2001-9.

18. **Seitz WH Jr, Damacen H.** Staged exchange arthroplasty for shoulder sepsis. *J Arthroplasty.* 2002 Jun;17(4 Suppl 1):36-40.

19. **Weber P, Utzschneider S, Sadoghi P, et al.** Management of the infected shoulder prosthesis: a retrospective analysis and review of the literature. *Intern Orthop.* 2011 Mar;35(3):365- 73.

20. **Sabesan VJ, Ho JC, Kovacevic D, Iannotti JP.** Two-stage Reimplantation for Treating Prosthetic Shoulder Infections. *Clin Orthop Relat Res.* 2011 Sep;469(9):2538-43.

21. **Abboud JA, Anakwenze OA, Hsu JE.** Soft-tissue Management in Revision Total Shoulder Arthroplasty. *J Am Acad Orthop Surg.* 2013 Jan;21(1):23-31.

22. **Wall B, Nove-Josserand L, O'Connor DP, et al.** Reverse total shoulder arthroplasty: A review of results according to etiol- ogy. J *Bone Joint Surg Am.* 2007 Jul;89(7):1475-85.

23. **Frankle M, Siegal S, Pupello D, et al.**The Reverse Shoulder Prosthesis for glenohumeral arthritis associated with severe rotator cuff deficiency: A minimum two-year follow-up study of sixty patients. *J Bone Joint Surg Am.* 2005 Aug;87(8);1697- 705.

24. **Sperling JW, Cofield RH, Torchia ME, Hanssen AD.** Infection after shoulder instability surgery. *Clin Orthop Relat Res.* 2003 Sep;(414):61-4.

25. **Sawyer JR, Esterhai JL Jr.** Shoulder infections. In: Warner JP, Ianottie JP, Gerber C, (eds): Complex and Revision Problems in Shoulder Surgery. Philadelphia, PA: Lippincott-Raven, 1997, pp. 385-398.

26. **Bosco JA III, Slover JD, Haas JP.** Perioperative strategies for decreasing infection: A comprehensive evidence-based- approach. *J Bone Joint Surg Am.* 2010 Jan;92(1):232-9.

27. **Chen AL, Shapiro JA, Ahn AK, et al.** Rotator Cuff repair in patients with type I diabetes mellitus. *J Shoulder Elbow Surg.* 2003 Sep-Oct;12(5):416-21.

28. **Kalainov DM, Bisson LJ, Brause BD, et al.** Management of infected shoulder arthroplasties. *Orthop Trans.* 1996;20:411- 12.

29. **Codd TP, Yamaguchi K, Pollock RG, et al.** Infected shoulder arthroplasties: Treatment with staged reimplantation vs. resec- tion arthroplasty. *Orthop Trans.* 1996;20:59.

30. **Themistocleus G, Zalavras C, Stine I, et al.** Prolonged im- plantation of an antibiotic cement spacer for management of shoulder sepsis in compromised patients. *J Shoulder Elbow Surg.* 2007 Nov-Dec;16(6):701-5.

31. **Brems JJ.** Complications of shoulder arthroplasty: Infections, instability, and loosening. *Instr Course Lect.* 2002;51:29-39.

32. **Sperling JW, Galatz LM, Higgins LD, et al.** Avoidance and treatment of complications in shoulder arthroplasty. *Instr Course Lect.* 2009;58:459-72.

33. **Wirth MA, Rockwood CA Jr.** Complications of total shoul- der-replacement arthroplasty. *J Bone Joint Surg Am.* 1996 Apr;78(4):603-16.

THE PREFORMED SPACERS: FROM THE IDEA TO THE REALIZATION OF AN INDUSTRIAL DEVICE

Renzo Soffiatti, PhD
Tecres, S.p.A.

www.exac.com/courses
August 26-27 | Advanced Surgical Solutions for Shoulder, Hip and Knee Arthroplasty **| Chicago, Ill.**

At the beginning of the 1990s, when visiting hospital operating rooms, it was possible to see surgeons modelling bone cement with their hands to obtain handmade devices with a prosthesis-like geometry. The device was created to temporarily replace removed septic prosthesis. The positioning in the septic site of an antibiotic bone cement device aimed to strengthen the systemic antibiotic therapy. Systemic antibiotic therapy is not always able to guarantee optimal antibiotic concentration in the infected site. Some months after implantation, the device was removed and replaced with a new prosthesis, giving back to the patient a healed joint and a certain functional recovery. This device was called a "spacer."[1,7,13,14]

MECHANICAL FAILURE

Unfortunately, in many cases, it was possible to see bad situations, determined by mechanical failure of the hand made devices. Although breakage was a feared and undesired complication, surgeons were very satisfied with the antiseptic effectiveness of the device. In other words, the spacer and the systemic treatment increased the probability of infection healing compared to systemic antibiotic therapy alone.

SPACER-G

These positive results led Tecres® to systematically research and study spacers made by the surgeon, and design a device that could be mechanically safe and pharmacologically effective at the same time. In other words, a "reproducible effective device" and a device that could also give the patient a better quality of life.

With these key features, the Spacer-G was designed (Figure 1). Its geometry was studied to permit an optimal interaction between the acetabulum and the femur. The anatomical stem-neck angle was chosen to limit dislocation as much as possible, the saddle shaped neck was designed to limit the possible acetabular protrusion and the extreme smoothness of the head meant to reduce the possible generation of debris. An inner stainless steel bar (Figure 2) was inserted to provide high mechanical strength and gentamicin was chosen as the antibiotic due to the wide

Figure 1. Spacer-S, shoulder spacer; Spacer-G, hip spacer; Spacer-K, knee spacer

Figure 2. Inner core present in Spacer-G

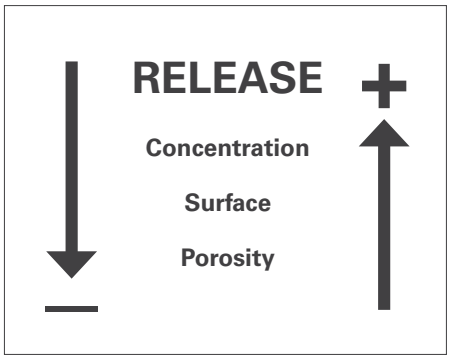

Figure 3. Factors influencing the release of antibiotic from a PMMA matrix

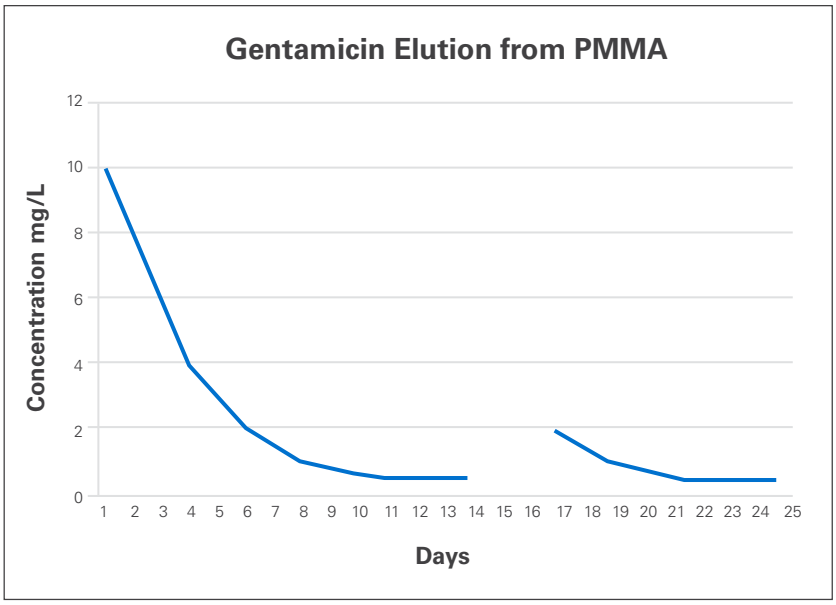

Figure 4. Elution kinetics of an antibiotic loaded cement, after an elution period in saline, the specimen is dried and left in the open air. A second elution period is then started showing an initial release higher than expected: the migration of the antibiotic in the PMMA matrix occurs also in absence of a liquid solvent.

spectrum of activity and the good properties of release from PMMA.

Mechanical and pharmacological testing confirmed the favorable performances of the device, which are solid and allows partial weight-bearing and releases effective amount of antibiotic in the infected site.[2,3,4,5,9] Soon after the first positive cases, the one-sized spacer was joined by a smaller and a bigger head size, which improved the head-acetabulum coupling and reduced dislocation. Then the long stem version was introduced, which allowed surgeons to use the device also in the absence of a proximal support, in the presence of large metaphyseal defects and after a transfemoral approach.[12]

KNEE, SHOULDER AND ELBOW SPACERS

The clinical success of the Spacer-G lead to the design of Spacer-K (Figure 1), a knee spacer with comparable performance. These temporary spacers are CE marked as Class III devices and are the first device of this type to have obtained FDA clearance (InterSpace® Hip; InterSpace® Knee; InterSpace® Shoulder). Based on these experiences and taking advantage of the same principles, the shoulder (Spacer-S) (Figure 1) and the elbow spacer (Spacer-E) were designed.

BONE CEMENT ELUTION FROM PMMA

The mechanism, or mechanisms, of antibiotic elution from PMMA are not yet clear. Therefore, it is more correct to speak of experimental observations that show the conditions which lead to an increase or decrease in the release of antibiotic. Synthetically, keeping fixed solvent and temperature, the increase of the release occurs when there is an:

- Increase in the concentration of the antibiotic in PMMA
- Increase in the surface at the interface cement-solvent
- Increase in the permeability of the cement matrix

Permeability = porosity + chemical/physical properties (of matrix)

A reduction in the release will occur when in the opposite situation (Figure 3).

For example, the preparation of bone cement under vacuum determines a reduction in the cement porosity and therefore a reduction in the antibiotic release.[10] In addition to the above mentioned parameters, other experimental observations show that the antibiotic (drug) molecule is able to migrate in the cement matrix even in the absence of a solvent following a diffusion behavior (Figure 4). The relation that better satisfies such experimental observations is the Fick's equation:

$$J = \frac{D\,(C1 - C2)}{X}$$



Figure 5. Spacer-G stem: left, old version with smooth surface; right, new version with textured surface



Figure 6. Bone cement powder: PMMA pearls are colorless, gentamicin sulphate pearls are blue

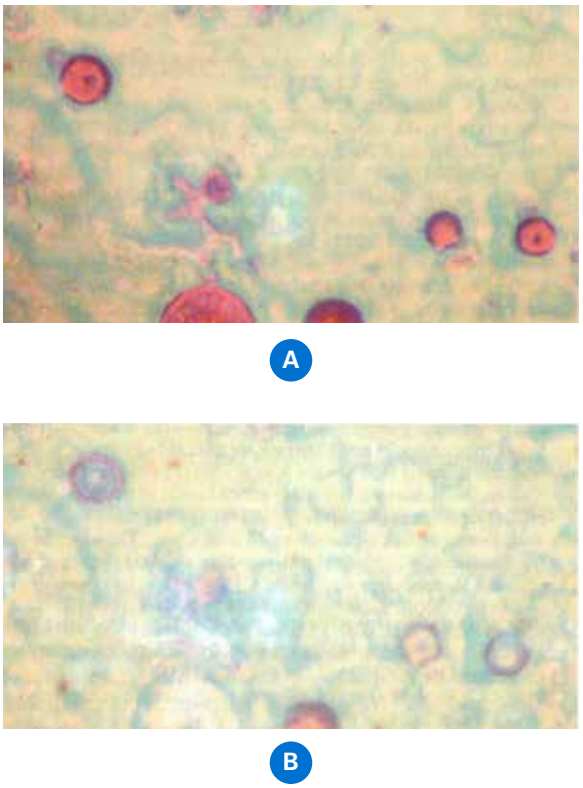

Figure 7. Cured gentamicin bone cement: A) reservoir with gentamicin in red; B) empty reservoir (after contact with solvent)

J is the molecular flux that is directly proportional to the diffusion coefficient (D), which depends from antibiotic matrix and temperature; interface area (A); concentration difference (C1 -C2) where C1> C2, and inversely proportional to the distance between C1 and C2 (X).

If we keep C and X constant, the formula becomes:

J = D A K

Therefore, if we want to increase the antibiotic release, it is sufficient to increase the diffusion coefficient D and the interface area A. This has been the route followed to design the new spacers.

HIGH-RELEASE MATRIX FOR THE SPACERS

In 2006, the distribution of the spacers with an increased antibiotic release started.[1] The absolute amount of antibiotic in the devices is identical, but the new spacers have an increased release capacity. The release can be as high as 4-5x the release of the previous spacers. This result has been achieved in two ways: 1) the external surface (i.e., the interface area with the biological liquids) has been increased thanks to a special finishing that increases the interface area. Figure 5 shows the surfaces of Spacer-G stem before and after; 2) the bone cement matrix that includes the antibiotic made with a new generation of polymers structured to increase permeability.

Before turning into a compact and solid structure, the spacer is a powder of spheroidal particles made of a mixture of PMMA, barium sulphate and gentamicin sulphate. Only with a colorimetric method it is possible to discriminate the components. Figure 6 shows a group of spheroidal particles which constitutes the powder used to manufacture the spacers. The colorless particles are PMMA, the blue ones are gentamicin. When the liquid monomer MMA is added to the powder, a mouldable dough is obtained that, in a few minutes, gets hard and solid. In the hardened mass, the spheroidal particles of PMMA cannot be distinguished any more, but the gentamicin ones can. Figure 7a shows the particles of gentamicin colored in red. Actually, these spheroidal particles act as micro reservoirs from which gentamicin flows outside the cement mass. Figure 7b shows the empty micro reservoir of genamicin after the contact with the solvent.

CONCLUSION

The constant work carried out over the years has led to an extension of the use of bone cement in fields hardly imaginable a few years ago. Today, it is possible to manufacture with this material medical devices with different properties that can be modulated at pleasure (Figure 8). Bone cement as a drug delivery system can be designed and specific elution kinetics can be achieved.

This aspect expands the concept of cementation, and with the right synergy among specialists of different disciplines, it will be possible to strengthen the surgical and therapeutic tools and increase the healing expectations of the patient. •

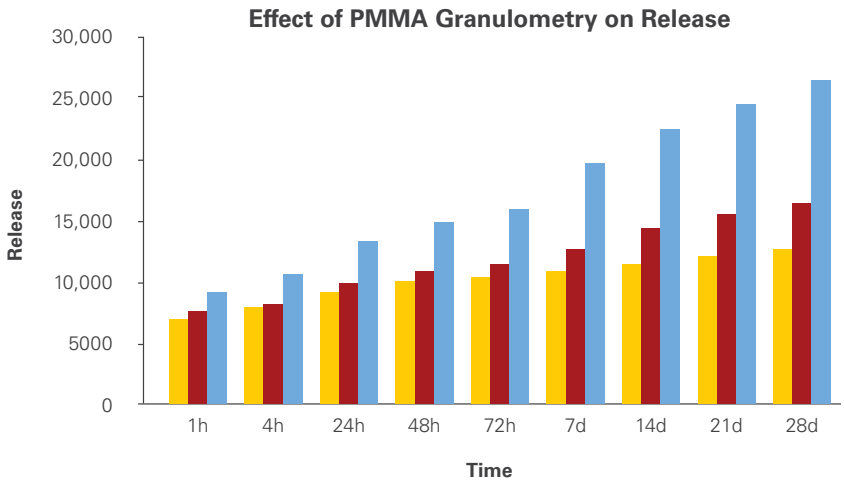

Figure 8. PMMA particle size is one of the properties that can be altered to change the antibiotic release. The chart depicts the change in gentamicin release when increasing the PMMA granulometry in three samples

REFERENCES

1. **Abendschein W** Salvage of infected total hip replacement: use of antibiotic/PMMA spacer. *Orthopedics* (1992) 15{2):228-229

2. **Affatato S, Mattarozzi A, Taddei P et al.** Investigations on the wear behavior of the temporary PMMA-based hip Spacer-G. *Proc Inst Mech Eng* (2003) IHI 217(1): 1-8

3. **Baleani M, Traina F, Toni A** The mechanical behaviour of a preformed hip spacer *Hip International* (2003) (13):159-162

4. **Bertazzoni Minelli E, Benini A, Magnan B et al.** Release of gentamicin and vancomycin from temporary human hip spacers in two-stage revision of infected arthroplasty *J Antimic rob Chemother* (2003) 53(2):329-334

5. **Bertazzoni Minelli E, Benini A, Magnan B et al.** Release of antibiotics and inhibitory activity in drainage fluids following temporary spacer implants in two-stage revision surgery Proceedings of ECCi (2005) Florence, Italy 19-22 October 2005

6. **Boda A.** Antibiotic irrigation-perfusion treatment for chronic osteomyelitis. *Arch Orthop Trauma Surg* (1979) 95(1-2):31-35

7. **Cohen JC,Hozack W, Cuckler JM et al.** Two-stage reimplantation of septic total knee arthroplasty.Report of three cases using an antibiotic-PMMA spacer block. J *Arthroplasty* (1988) 3(4):369-377

8. **Henry SL, Ostermann PA, Seligson D.** The prophylactic use of antibiotic impregnated beads in open fractures. *J Trauma* (1990) 30(10):1231-1238

9. **Magnan B, Regis D, Biscaglia R et al.** Preformed acrylic bone cement spacer loaded with antibiotics: use of two-stage procedure in IO patients because of infected hips after total replacement. *Acta Orthop Scand* (2001) 72(6):591-594

10. **Neut R, Van de Belt H, Van Horn JR et al.** The effect of mixing on gentamicin release from polymethylmethacrylate bone cements. *Acta Orthop Scand* (2003) 74(6):670 - 676

11. **Ohtsuka H, Yokoyama K, Higashi K et al.** (2002) Use of antibiotic impregnated bone cement nail to treat septic nonunion after open tibial fracture. *J Trauma* 52(2}:364 -366

12. **Romano C, Meani E.** The use of preformed long stem antibiotic loaded cement spacers and modular non-cemented prosthesis for two-stage revisions of infected hip prosthesis Proceedings of the AAOS (2004) San Francisco (USA)

13. **Wilde AH, Ruth JT.** Two-stage reimplantation in infected total knee arthroplasty.*Clin Orthop Relat Res* (1988) (236):23-35

14. **Zilkens KW, Casser HR, Ohnsorge J.** Treatment of an old infection in a total hip replacement with an interim spacer prosthesis. *Arch Orthop Trauma Surg* (1990) 109(2):94-96.

Complexity Simplified.

Revision cases can be complex and challenging. Exactech's latest revision products for hip, knee and shoulder are designed to deliver ease of use for surgeons and improved outcomes for patients. Whatever demands you face in the O.R., Exactech products can help you resolve them. ***Complexity Simplified.***

Visit www.exac.com for more information.

Exactech®

Surgeon focused. Patient driven.™

AAOS Annual Meeting • Booth 3881 • March 2-4, 2016

Used in more than 1 MILLION PATIENTS since 2012

With EXPAREL, we are able to deliver pain relief without catheters or pumps, and our opioid use has greatly decreased.

— Stephan J. Finical, MD
Charlotte, North Carolina

Experience the impact:

Reduce the need for opioids while providing long-lasting postsurgical pain control—all from a single dose.

The clinical benefit of the decrease in opioid consumption has not been demonstrated.

EXPAREL is indicated for single dose administration into the surgical site to produce postsurgical analgesia.

Important Safety Information

EXPAREL is contraindicated in obstetrical paracervical block anesthesia. EXPAREL has not been studied for use in patients younger than 18 years of age. Non-bupivacaine-based local anesthetics, including lidocaine, may cause an immediate release of bupivacaine from EXPAREL if administered together locally. The administration of EXPAREL may follow the administration of lidocaine after a delay of 20 minutes or more. Other formulations of bupivacaine should not be administered within 96 hours following administration of EXPAREL. Monitoring of cardiovascular and neurological status, as well as vital signs should be performed during and after injection of EXPAREL as with other local anesthetic products. Because amide-type local anesthetics, such as bupivacaine, are metabolized by the liver, EXPAREL should be used cautiously in patients with hepatic disease. Patients with severe hepatic disease, because of their inability to metabolize local anesthetics normally, are at a greater risk of developing toxic plasma concentrations.
In clinical trials, the most common adverse reactions (incidence ≥10%) following EXPAREL administration were nausea, constipation, and vomiting. Studies demonstrating the safety and efficacy of EXPAREL were conducted in hemorrhoidectomy and bunionectomy; EXPAREL has not been demonstrated to be safe and effective in other procedures.

Please see brief summary of Prescribing Information on reverse side.
For more information, please visit **www.EXPAREL.com** or call 1-855-RX-EXPAREL (793-9727).

Data on file. Parsippany, NJ: Pacira Pharmaceuticals, Inc.; February 2015.

EXPAREL®
(bupivacaine liposome injectable suspension)
PATIENT-FOCUSED PAIN CONTROL

©2015 Pacira Pharmaceuticals, Inc., Parsippany, NJ 07054
PP-EX-US-0973 07/15

EXPAREL®

(bupivacaine liposome injectable suspension)

Brief Summary
(For full prescribing information refer to package insert)

INDICATIONS AND USAGE

EXPAREL is a liposome injection of bupivacaine, an amide-type local anesthetic, indicated for administration into the surgical site to produce postsurgical analgesia.

EXPAREL has not been studied for use in patients younger than 18 years of age.

CONTRAINDICATIONS

EXPAREL is contraindicated in obstetrical paracervical block anesthesia. While EXPAREL has not been tested with this technique, the use of bupivacaine HCl with this technique has resulted in fetal bradycardia and death.

WARNINGS AND PRECAUTIONS

Warnings and Precautions Specific for EXPAREL

As there is a potential risk of severe life-threatening adverse effects associated with the administration of bupivacaine, EXPAREL should be administered in a setting where trained personnel and equipment are available to promptly treat patients who show evidence of neurological or cardiac toxicity.

Caution should be taken to avoid accidental intravascular injection of EXPAREL. Convulsions and cardiac arrest have occurred following accidental intravascular injection of bupivacaine and other amide-containing products.

Using EXPAREL followed by other bupivacaine formulations has not been studied in clinical trials. Other formulations of bupivacaine should not be administered within 96 hours following administration of EXPAREL.

EXPAREL has not been evaluated for the following uses and, therefore, is not recommended for these types of analgesia or routes of administration.

- epidural
- intrathecal
- regional nerve blocks
- intravascular or intra-articular use

EXPAREL has not been evaluated for use in the following patient population and, therefore, it is not recommended for administration to these groups.

- patients younger than 18 years old
- pregnant patients
- nursing patients

The ability of EXPAREL to achieve effective anesthesia has not been studied. Therefore, EXPAREL is not indicated for pre-incisional or pre-procedural loco-regional anesthetic techniques that require deep and complete sensory block in the area of administration.

ADVERSE REACTIONS

Adverse Reactions Reported in All Wound Infiltration Clinical Studies

The safety of EXPAREL was evaluated in 10 randomized, double-blind, local administration into the surgical site clinical studies involving 823 patients undergoing various surgical procedures. Patients were administered a dose ranging from 66 to 532 mg of EXPAREL. In these studies, the most common adverse reactions (incidence greater than or equal to 10%) following EXPAREL administration were nausea, constipation, and vomiting.

The common adverse reactions (incidence greater than or equal to 2% to less than 10%) following EXPAREL administration were pyrexia, dizziness, edema peripheral, anemia, hypotension, pruritus, tachycardia, headache, insomnia, anemia postoperative, muscle spasms, hemorrhagic anemia, back pain, somnolence, and procedural pain.

DRUG INTERACTIONS

EXPAREL can be administered undiluted or diluted up to 0.89 mg/mL (i.e., 1:14 dilution by volume) with normal (0.9%) sterile saline for injection or lactated Ringer's solution. EXPAREL must not be diluted with water or other hypotonic agents as it will result in disruption of the liposomal particles.

EXPAREL should not be admixed with other local anesthetics.

EXPAREL may be locally administered after at least 20 minutes following local administration of lidocaine.

Bupivacaine HCl, when injected immediately before EXPAREL, may impact the pharmacokinetic and/or physicochemical properties of the drugs if the milligram dose of bupivacaine HCl solution exceeds 50% of the EXPAREL dose. The toxic effects of these drugs are additive and their administration should be used with caution including monitoring for neurologic and cardiovascular effects related to toxicity.

EXPAREL should not be admixed with other drugs prior to administration.

USE IN SPECIFIC POPULATIONS

Pregnancy Category C

Risk Summary

There are no adequate and well-controlled studies of EXPAREL in pregnant women. Animal reproduction studies have been conducted to evaluate bupivacaine. In these studies, subcutaneous administration of bupivacaine to rats and rabbits during organogenesis was associated with embryo-fetal deaths in rabbits at a dose equivalent to the maximum recommended human dose (MRHD). Subcutaneous administration of bupivacaine to rats from implantation through weaning, also at an MRHD-equivalent dose, produced decreased pup survival. EXPAREL should be used during pregnancy only if the potential benefit justifies the potential risk to the fetus.

Clinical Considerations

Labor or Delivery

Bupivacaine is contraindicated for obstetrical paracervical block anesthesia. While EXPAREL has not been studied with this technique, the use of bupivacaine for obstetrical paracervical block anesthesia has resulted in fetal bradycardia and death.

Bupivacaine can rapidly cross the placenta, and when used for epidural, caudal, or pudendal block anesthesia, can cause varying degrees of maternal, fetal, and neonatal toxicity. The incidence and degree of toxicity depend upon the procedure performed, the type, and amount of drug used, and the technique of drug administration. Adverse reactions in the parturient, fetus, and neonate involve alterations of the central nervous system, peripheral vascular tone, and cardiac function.

Data

Animal Data

Bupivacaine hydrochloride was administered subcutaneously to rats at doses of 4.4, 13.3, and 40 mg/kg/day and to rabbits at doses of 1.3, 5.8, and 22.2 mg/kg/day during the period of organogenesis (implantation to closure of the hard palate). No embryo-fetal effects were observed in rats at the doses tested with the high dose causing increased maternal lethality. An increase in embryo-fetal deaths was observed in rabbits at the high dose in the absence of maternal toxicity. This dose is clinically relevant as is comparable to the MRHD based on Body Surface Area (BSA) comparisons.

In a rat pre- and post-natal development study conducted at subcutaneous doses of 4.4, 13.3, and 40 mg/kg/day with dosing from implantation through weaning (during pregnancy and lactation), decreased pup survival was observed at the high dose, a clinically relevant dose as it is comparable to the MRHD based on BSA comparisons.

Nursing Mothers

Published literature reports that bupivacaine is present in human milk at low levels; however, the drug is poorly absorbed orally. Exercise caution when administering EXPAREL to a nursing woman.

Pediatric Use

Safety and effectiveness in pediatric patients below the age of 18 have not been established.

Geriatric Use

Of the total number of patients in the EXPAREL wound infiltration clinical studies (N=823), 171 patients were greater than or equal to 65 years of age and 47 patients were greater than or equal to 75 years of age. No overall differences in safety or effectiveness were observed between these patients and younger patients. Clinical experience with EXPAREL has not identified differences in efficacy or safety between elderly and younger patients, but greater sensitivity of some older individuals cannot be ruled out.

Hepatic Impairment

Because amide-type local anesthetics, such as bupivacaine, are metabolized by the liver, these drugs should be used cautiously in patients with hepatic disease. Patients with severe hepatic disease, because of their inability to metabolize local anesthetics normally, are at a greater risk of developing toxic plasma concentrations.

Renal Impairment

Bupivacaine is known to be substantially excreted by the kidney, and the risk of toxic reactions to this drug may be greater in patients with impaired renal function. Care should be taken in dose selection of EXPAREL.

OVERDOSAGE

In the clinical study program, maximum plasma concentration (C_{max}) values of approximately 34,000 ng/mL were reported and likely reflected inadvertent intravascular administration of EXPAREL or systemic absorption of EXPAREL at the surgical site. The plasma bupivacaine measurements did not discern between free and liposomal-bound bupivacaine making the clinical relevance of the reported values uncertain; however, no discernable adverse events or clinical sequelae were observed in these patients.

DOSAGE AND ADMINISTRATION

EXPAREL is intended for single-dose administration only. The recommended dose of EXPAREL is based on the surgical site and the volume required to cover the area.

Surgery	Dose of EXPAREL	Volume of EXPAREL
Bunionectomy[1]	106 mg	8 mL
Hemorrhoidectomy[2]	266 mg	20 mL

[1]Infiltrate 7 mL of EXPAREL into the tissues surrounding the osteotomy and 1 mL into the subcutaneous tissue.

[2]Dilute 20 mL of EXPAREL with 10 mL of saline, for a total of 30 mL, and divide the mixture into six 5 mL aliquots. Perform the anal block by visualizing the anal sphincter as a clock face and slowly infiltrating one aliquot to each of the even numbers.

Administration Precautions

Admixing EXPAREL with other drugs prior to administration is not recommended.

- Non-bupivacaine based local anesthetics, including lidocaine, may cause an immediate release of bupivacaine from EXPAREL if administered together locally. The administration of EXPAREL may follow the administration of lidocaine after a delay of 20 minutes or more.
- Bupivacaine HCl, when injected immediately before EXPAREL, may impact the pharmacokinetic and/or physicochemical properties of the drugs if the milligram dose of bupivacaine HCl solution exceeds 50% of the EXPAREL dose. The toxic effects of these drugs are additive and their administration should be used with caution including monitoring for neurologic and cardiovascular effects related to toxicity.
- When a topical antiseptic such as povidone iodine (e.g., Betadine®) is applied, the site should be allowed to dry before EXPAREL is administered into the surgical site. EXPAREL should not be allowed to come into contact with antiseptics such as povidone iodine in solution.

Studies conducted with EXPAREL demonstrated that the most common implantable materials (polypropylene, PTFE, silicone, stainless steel, and titanium) are not affected by the presence of EXPAREL any more than they are by saline. None of the materials studied had an adverse effect on EXPAREL.

Non-Interchangeability with Other Formulations of Bupivacaine

Different formulations of bupivacaine are not bioequivalent even if the milligram dosage is the same. Therefore, it is not possible to convert dosing from any other formulations of bupivacaine to EXPAREL and vice versa.

Dosing in Special Populations

EXPAREL has not been studied in patients younger than 18 years of age, pregnant patients or patients who are nursing.

CLINICAL PHARMACOLOGY

Pharmacokinetics

Local infiltration of EXPAREL results in significant systemic plasma levels of bupivacaine which can persist for 96 hours. Systemic plasma levels of bupivacaine following administration of EXPAREL are not correlated with local efficacy.

CLINICAL STUDIES

The efficacy of EXPAREL was compared to placebo in two multicenter, randomized, double-blinded clinical trials. One trial evaluated the treatments in patients undergoing bunionectomy; the other trial evaluated the treatments in patients undergoing hemorrhoidectomy. EXPAREL has not been demonstrated to be safe and effective in other procedures.

Bunionectomy

A multicenter, randomized, double-blind, placebo-controlled, parallel-group study evaluated the safety and efficacy of 106 mg EXPAREL in 193 patients undergoing bunionectomy. The mean age was 43 years (range 18 to 72). Study medication was administered directly into the wound at the conclusion of the surgery, prior to wound closure. Pain intensity was rated by the patients on a 0 to 10 numeric rating scale (NRS) out to 72 hours. Postoperatively, patients were allowed rescue medication (5 mg oxycodone/325 mg acetaminophen orally every 4 to 6 hours as needed) or, if that was insufficient within the first 24 hours, ketorolac (15 to 30 mg IV). The primary outcome measure was the area under the curve (AUC) of the NRS pain intensity scores (cumulative pain scores) collected over the first 24 hour period. There was a significant treatment effect for EXPAREL compared to placebo.

In this clinical study, EXPAREL demonstrated a significant reduction in pain intensity compared to placebo for up to 24 hours. The difference in mean pain intensity between treatment groups occurred only during the first 24 hours following study drug administration. Between 24 and 72 hours after study drug administration, there was minimal to no difference between EXPAREL and placebo treatments on mean pain intensity.

Hemorrhoidectomy

A multicenter, randomized, double-blind, placebo-controlled, parallel-group study evaluated the safety and efficacy of 266 mg EXPAREL in 189 patients undergoing hemorrhoidectomy. The mean age was 48 years (range 18 to 86). Study medication was administered directly into the wound (greater than or equal to 3 cm) at the conclusion of the surgery. Pain intensity was rated by the patients on a 0 to 10 NRS at multiple time points up to 72 hours. Postoperatively, patients were allowed rescue medication (morphine sulfate 10 mg intramuscular every 4 hours as needed). The primary outcome measure was the AUC of the NRS pain intensity scores (cumulative pain scores) collected over the first 72 hour period. There was a significant treatment effect for EXPAREL compared to placebo.

In this clinical study, EXPAREL demonstrated a significant reduction in pain intensity compared to placebo for up to 24 hours. The difference in mean pain intensity between treatment groups occurred only during the first 24 hours following study drug administration. Between 24 and 72 hours after study drug administration, there was minimal to no difference between EXPAREL and placebo treatments on mean pain intensity; however, there was an attendant decrease in opioid consumption, the clinical benefit of which was not demonstrated.

Pacira Pharmaceuticals, Inc.
San Diego, CA 92121 USA

Patent Numbers:
6,132,766 5,891,467
5,766,627 8,182,835

Trademark of Pacira Pharmaceuticals, Inc.

PACIRA
PHARMACEUTICALS, INC.

For additional information call
1-855-RX-EXPAREL (1-855-793-9727)

Rx only **May 2015**

Let Us Help Build Your Brand

Exactech's Practice Marketing Program

We offer all levels of support to help you create market awareness, drive patient interest and enhance physician referrals.

- Direct Mail Pieces
- Print & Digital Advertisments
- Custom Presentations
- Media Coverage
- Promotional Collateral
- Videos & Website Development

Contact your Exactech sales representative for marketing opportunities available in your area. Fees may apply.

Exactech®
Surgeon focused. Patient driven.™

For more information, contact your Exactech sales representative or email **practice.support@exac.com**

GET BACK TO WHAT YOU LOVE

Five Free Ways Exactech Can Help You Educate Your Patients

1. Brochures
2. Exam Room Posters
3. Joint Models
4. Website Content
5. Community Outreach

BIOLOX® inside
Beyond comparison since 1974

The Preferred Bearing Couple for Active Patients*

BIOLOX® ceramics worldwide have been successful in hip replacements for more than 40 years.

- **Excellent biological behavior***
- **No known risk of allergy***
- **No concerns about Co, Cr, and Ni ion release***
- **Reduced risk for PJI revisions***
- **No known pathogenic reaction to ceramic particles***
- **Significantly lower taper corrosion***

*References available on file at CeramTec GmbH on request.

CeramTec
THE CERAMIC EXPERTS

BIOLOX® is a registered trademark.
© 2015 CeramTec GmbH www.biolox.com

VuMedi

www.vumedi.com

VuMedi is a **video education** platform for Orthopaedic Surgeons.

Over **65,000 Surgeons** use VuMedi to improve patient are and grow their practice.

- ✔ New advances
- ✔ Challenging Treatments and Diagnostics
- ✔ Rare Pathologies and Complications
- ✔ Ask 1,000's of Other Doctors or Privately Message an Expert

...and much more

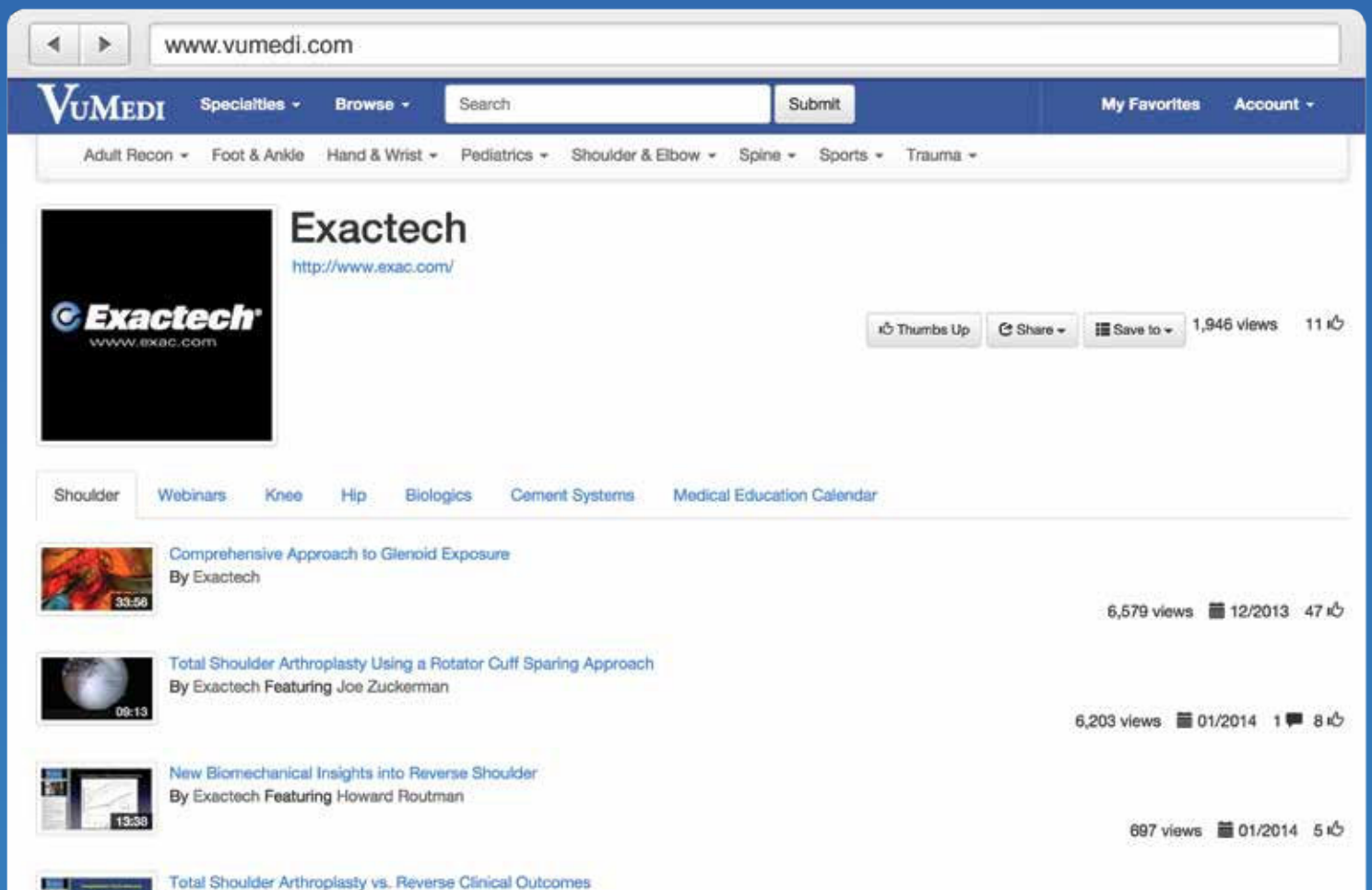

You are invited to Experience Exactech in Gainesville or in Surgery

Our experts are eager to listen to your concerns, learn about your clinical needs and respond with innovative solutions.

Arrange for surgery observation with one of your clinician colleagues or come to Gainesville and

- Attend in-depth meetings with members of the leadership, product development and engineering teams.
- Tour our research, manufacturing and testing laboratories.
- Gain hands-on experience in our surgical training center.

For more information or to schedule your surgeon-to-surgeon training or Exactech tour, please contact visits@exac.com.

Exactech®
Surgeon focused. Patient driven.™

ADVERTISER INDEX

This edition of *Innovations* is brought to you by Exactech, Inc. Below you'll find an alphabetical listing of the advertisers in this issue. We'd like to thank all of our advertisers and contributors for their support.

Advertiser	Page	Advertiser	Page	Advertiser	Page
CeramTec	57	Innomed	Back Cover	VuMedi	58
ICJR.net	Inside Front Cover	Pacira Pharmaceuticals, Inc.	54		

Sarraf TiN Coated Cement Removal Forceps *New!*

Designed by Khaled M. Sarraf, MD

Ultra hard titanium nitride coating helps to extend forceps life by increasing surface hardness, prolonging sharpness, and resisting chemicals and corrosion, while helping to eliminate metal transfer and protect the implant surface

PRODUCT NO:
5039 *Overall Length: 6"*

PROUDLY MADE IN THE USA

Cobb Elevators

PROUDLY MADE IN THE USA

PRODUCT NO'S:
3436 [1/2"] *Overall Length: 11"*
3438 [1"] *Overall Length: 11"*

Ultra hard titanium nitride coating helps to extend blade life by increasing surface hardness, prolonging sharpness, and resisting chemicals and corrosion.

Bradley Periosteal Elevator

Designed by Gary W. Bradley, MD

PRODUCT NO:
4720 *Overall Length: 11"*

Ultra hard titanium nitride coating helps to extend blade life by increasing surface hardness, prolonging sharpness, and resisting chemicals and corrosion.

PROUDLY MADE IN THE USA

Rivero Anti-Rotation Corkscrew Femoral Head Remover

Designed to help prevent rotation while engaging a femoral head for removal *New!*

The sharp-toothed sleeve can be tapped in to help provide purchase of the femoral head, then held to help prevent rotation as the super-threaded corkscrew is turned to engage the head for removal.

PROUDLY MADE IN THE USA

PRODUCT NO:
3705 *Overall Length: 10" (25,4cm)*

Designed by Dennis Rivero, MD



Dorr Hip Instruments

Designed by Lawrence D. Dorr, MD

PROUDLY MADE IN THE USA

Dorr Curved Hohmann Acetabular Retractor

Placed over the top of the piriformis, helps retract the gluteus medius.

Dorr Narrow Bent Acetabular Retractors

Retracts the gluteus maximus off the trochanter and exposes the back of the greater trochanter. The long version is used with larger patients.

Dorr Bent Hohmann Acetabular Retractor

Placed between the capsule and outer external oblique muscle to protect medial circumflex vessels. The tip engages the condyloid notch bone (teardrop). Helps retract soft tissues during acetabular exposure.

PRODUCT NO'S:	
1	D6105 [Dorr Curved Hohmann Acetabular] *Blade Width: 18.5mm* *Overall Length: 14"* *Depth from Handle: 4.5"*
2	D6108 [Dorr Narrow Bent Acetabular—Long] *Overall Length: 14.75"* *Depth from Handle: 6"* *Blade Width: 12.6mm*
3	D6110 [Dorr Narrow Bent Acetabular] *Overall Length: 15"* *Depth from Handle: 4.75"* *Blade Width at Widest: 12mm*
4	D6112 [Dorr Bent Hohmann Acetabular] *Overall Length: 14.5"* *Depth from Handle: 6"* *Blade Width: 21mm*

Dorr Curved Blade Bent Hohmann Retractors

Used for both femoral exposure—placed around the femoral neck or beneath the top of the femoral head—and acetubular exposure—posterior superior of the acetabulum.

Upward Double Bent Hohmann Retractor

Tapped into the illum to help retract the femur for acetabular exposure.

PRODUCT NO'S:	
5	D6106 [Dorr Curved Blade Bent Hohmann] *Overall Length: 13.5"* *Depth from Handle: 4.5"* *Blade Width: 40mm*
6	D6107 [Dorr Curved Blade Double Bent Hohmann] *Overall Length: 8.5"* *Depth from Handle: 5"* *Blade Width: 25mm*
7	D6114 [Upward Double Bent Hohmann] *Overall Length: 14"* *Depth from Flat Part of Handle: 5.5"* *Blade Width: 20.5mm*



Dorr Posterior Capsule and Sciatic Nerve Protection Retractors

Sits on the outer rim of the posterior inferior ishium to retract the posterior capsule for acetabular exposure and help to protect the sciatic nerve.

PRODUCT NO'S:	
	Overall Length: 14" *Depth from Handle: 6"* *Blade Width at Widest: 44mm*
8	D6109-L [Dorr Posterior Capsule and Sciatic Nerve Protection Retractor—Left]
9	D6109-R [Dorr Posterior Capsule and Sciatic Nerve Protection Retractor—Right]

Dorr Femoral Neck Elevators

Placed under the proximal femur to help expose the femoral head. The wide version is useful with large patients, while the narrow is useful when broaching or when the implant is in place.

PRODUCT NO'S:	
10	D6111 [Dorr Wide Femoral Neck Elevator] *Overall Length: 15"* *Depth from Handle: 2"* *Blade Width at Widest: 45mm*
11	D6113 [Dorr Narrow Femoral Neck Elevator] *Overall Length: 13.75"* *Depth from Handle: 2.25"* *Blade Width: 25mm*

ISO 9001:2008 • ISO 13485:2003

Scan to Launch Our Website

FREE TRIAL ON MOST INSTRUMENTS

INNOMED®

© 2015 Innomed, Inc.

103 Estus Drive, Savannah, GA 31404
www.innomed.net info@innomed.net
912.236.0000 Phone
912.236.7766 Fax
Innomed-Europe Tel. +41 41 740 67 74
Fax +41 41 740 67 71
1.800.548.2362