



Vertical/Horizontal Ridge Reconstruction

Series B, Number 2

JAMES G. WILSON, DMD, *Tampa, Florida*

Presentation

A 73-year-old female presented with a chief complaint of pain on chewing on tooth #9. Examination revealed that teeth #'s 9-12 had a hopeless prognosis due to advanced periodontal breakdown. The recommendation for extraction of teeth #'s 9-12, ridge augmentation, and an implant reconstruction was initially declined. Alternatively, the patient chose to have teeth #'s 9 and 10 removed and a transitional removable partial denture fabricated. At four months of healing and wearing the removable appliance, the patient was unhappy and requested the proposed fixed implant therapy. The patient's therapy included extraction of teeth #'s 11-12, guided bone regeneration therapy using Regenaform moldable allograft paste and three (3) implants.

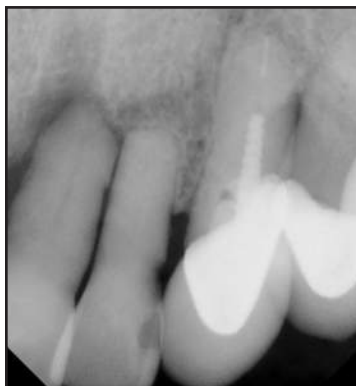

FIG. 1: Pre-treatment radiograph of hopeless teeth #9-10.

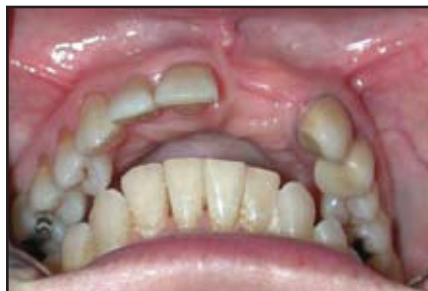

FIG. 2: 4 month post-extractions and healing of teeth #9 and #10.

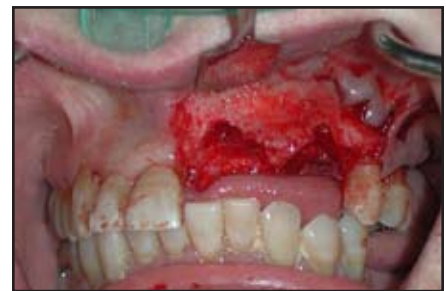

FIG. 3: The extent of osseous destruction is evident at the time of grafting procedure.

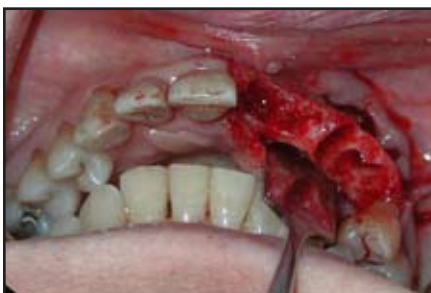

FIG. 4: Occlusal view of the osseous irregularities.

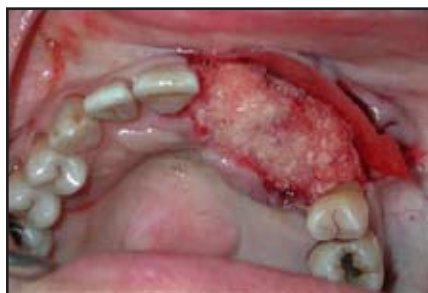

FIG. 5: A 2cc block of Regenaform was utilized to graft the surgical site.

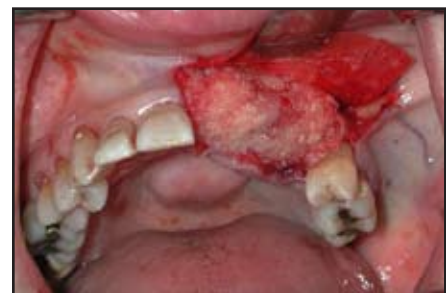

FIG. 6: A buccally fixated collagen membrane was utilized to isolate and prevent soft tissue ingrowth.

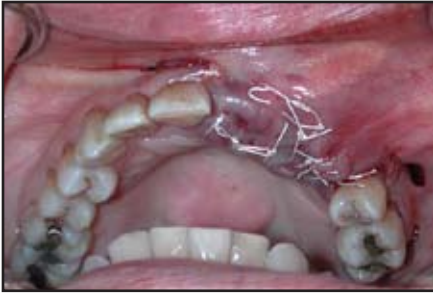

FIG. 7: Passive primary closure was achieved utilizing a Gore™ non-resorbable suture.

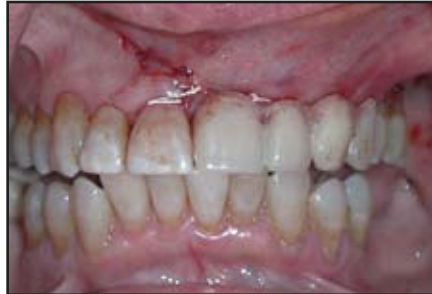

FIG. 8: The patient's existing flipper was modified with the addition of teeth #11 & #12 and was relieved to keep all compressive forces off of the graft, thus ensuring no compromise to the graft's vascularity.

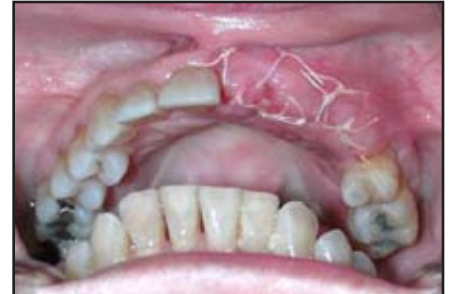

FIG. 9: Two weeks post operative healing.

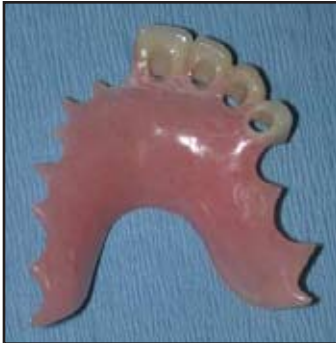

FIG. 10: The patient's flipper was utilized as a surgical stent for implant placement.

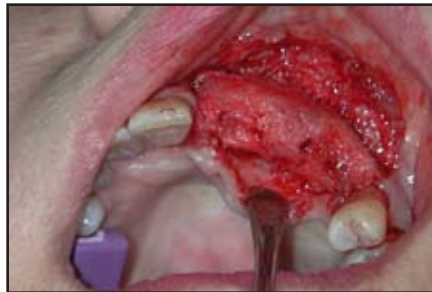

FIG. 11: Osseous ridge marked for implant placement preparation, 4 1/2 months post-grafting procedure.

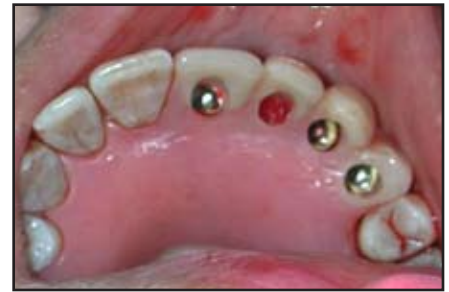

FIG. 12: Three Steri-Oss™ implants in place.

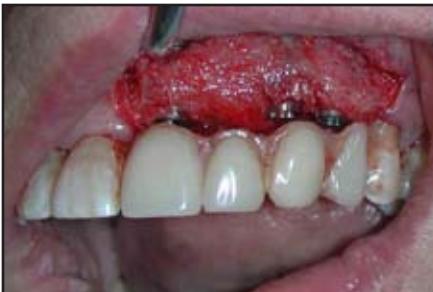

FIG. 13: Facial view of implant placement.

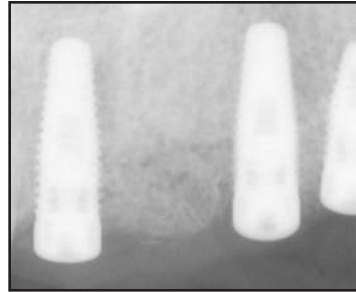


FIG. 14: Radiograph of implants in place.

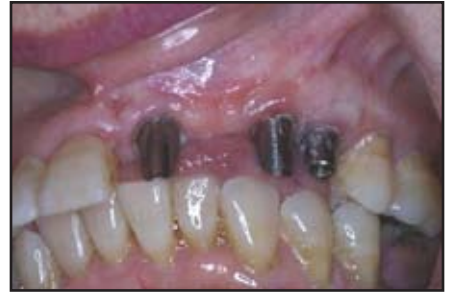

FIG. 15: Abutments in place.

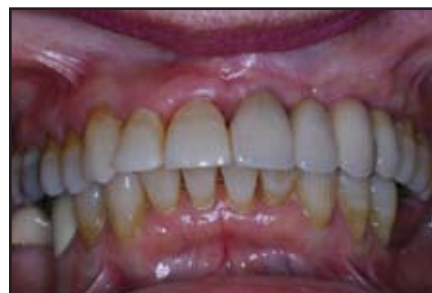

FIG. 16: Two year post surgical restoration.

Gore™ is the registered trademark of W.L. Gore & Associates, Inc.

Steri-Oss™ is a registered trademark of Nobel Biocare.

Regenaform® is processed by Regeneration Technologies and distributed by Exactech.

Exactech®

2320 NW 66th Court
Gainesville, Florida 32653
1-866-284-9690 www.exac.com

©2006 Exactech, Inc.
717-00-67 0306