



Treatment of Endo/Perio Defect with Regenaform[®]

Series B, Number 1

BRIAN HOLLANDER, DDS, MS *Novato, California*

Presentation

A 47 year old male presents with tooth number 19 exhibiting a twelve-millimeter buccal pocket, mesial root radiolucency, and a large three surface restoration.

The patient was advised of the endo/perio complication and was given the option of endodontic and periodontal treatment or extraction followed by an osseointegrated implant. The patient opted for the extraction with a Regenaform bone graft followed by the implant placement.

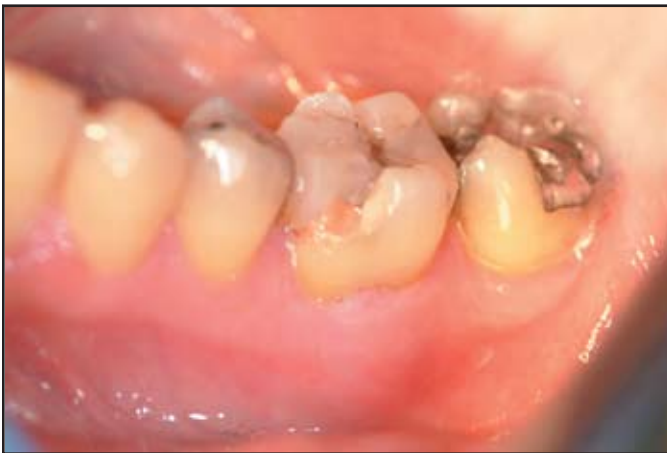

FIG. 1: Pre-treatment view of tooth #19.

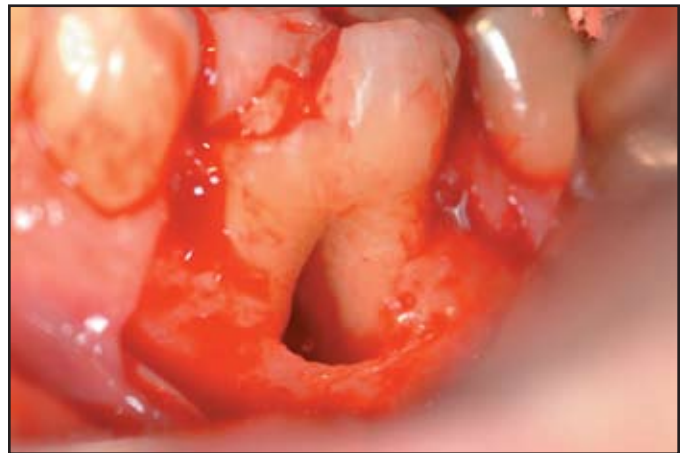


FIG. 2: Reflected flap showing extent of furcation involvement and overall bone loss.

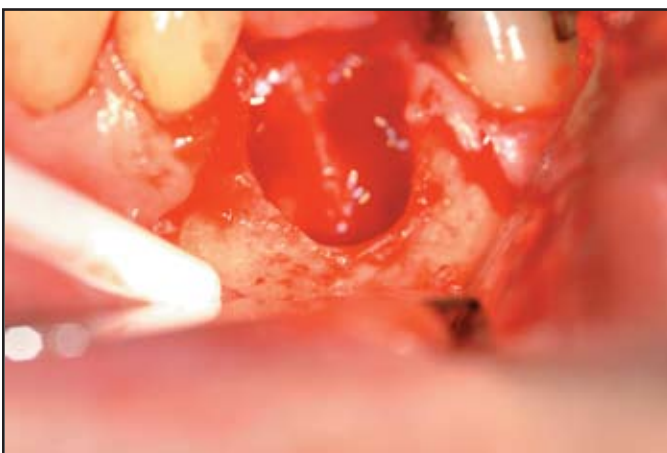

FIG. 3: Full view of bony defect post-extraction. Note large amount of buccal bone loss.

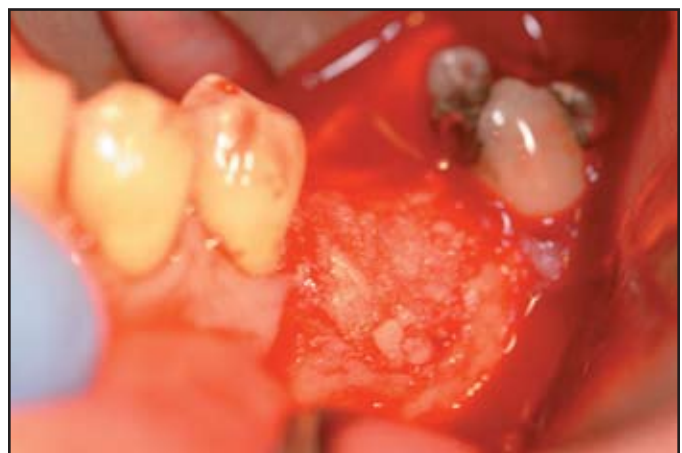

FIG. 4: Placement of 1cc Regenaform graft in surgical site.

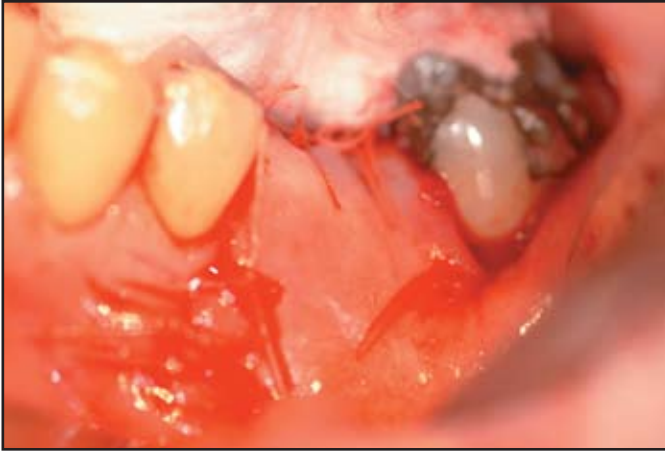


FIG. 5: Placement of Bio-Gide™ resorbable membrane and suture of surgical site.

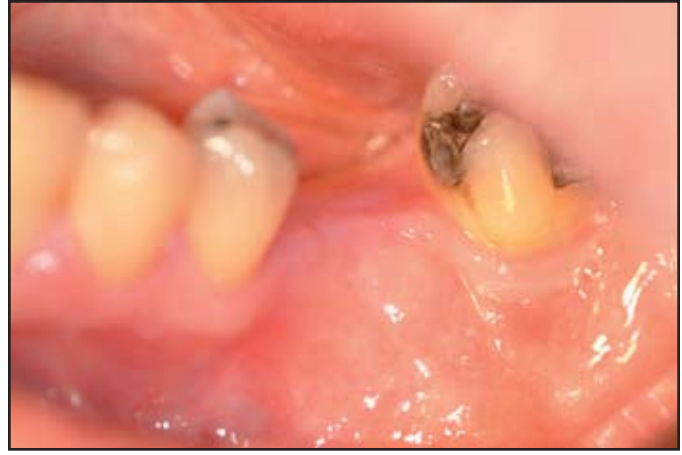

FIG. 6: Surgical site 6 month post-operative healing.

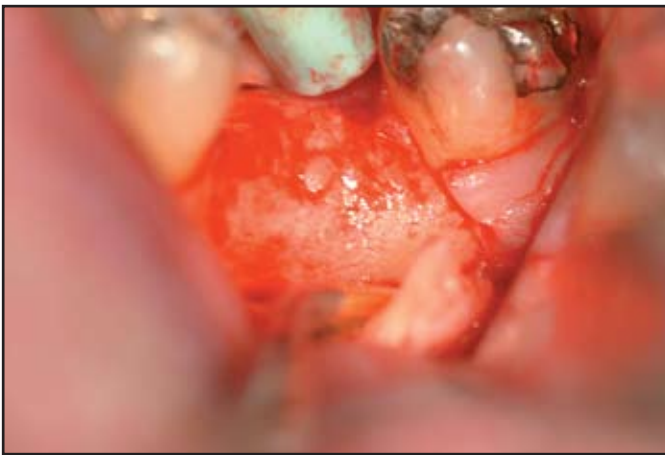

FIG. 7: Surgical re-entry of regenerated ridge at 6 months. Note complete repair of buccal cortex.

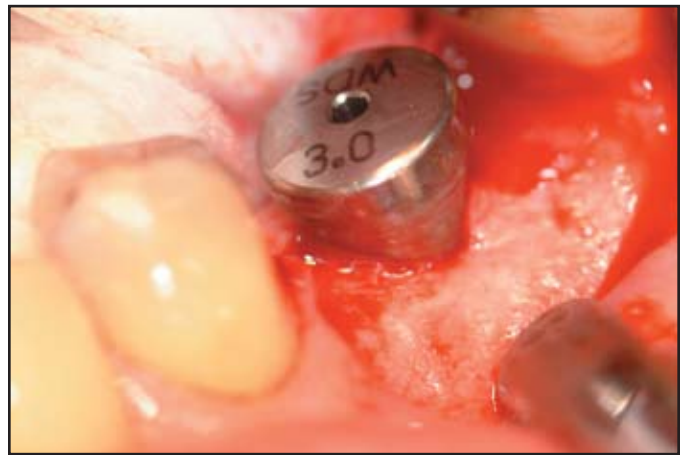


FIG. 8: A 4.8mm x 10mm Lifecore Biomedical implant is placed.

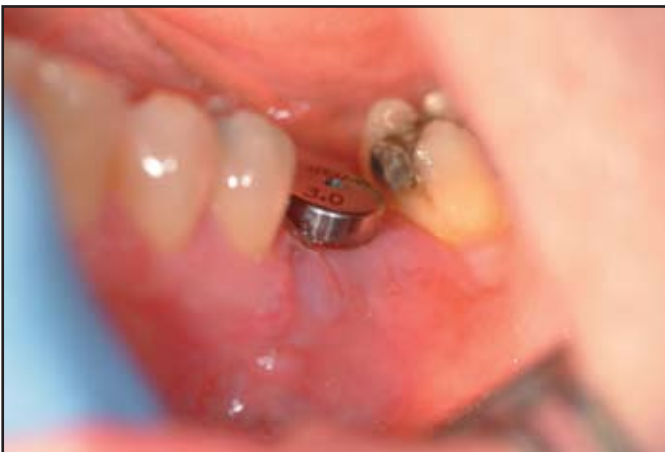

FIG. 9: 1 week post-operative implant placement follow up.