Guided Bone Regeneration Using Regenaform for Implant Site Development

Series A, Number 2

JEFFREY LEMLER, D.D.S.
New York City, NY

Presentation

A patient presented with inadequate lateral and vertical dimension in the left posterior mandible. The goal was to regenerate the edentulous site in order to facilitate the placement of endosseous root form implants.

The determining factor for proper implant positioning is dependant on the amount of available bone. In order to optimize implant reconstruction, the clinician must address the challenge of the deficient endentulous ridge from the perspective of lateral and vertical bone deficiencies. Guided Bone Regeneration (GBR) techniques allow bone cells to populate a space isolated and protected by a barrier membrane.

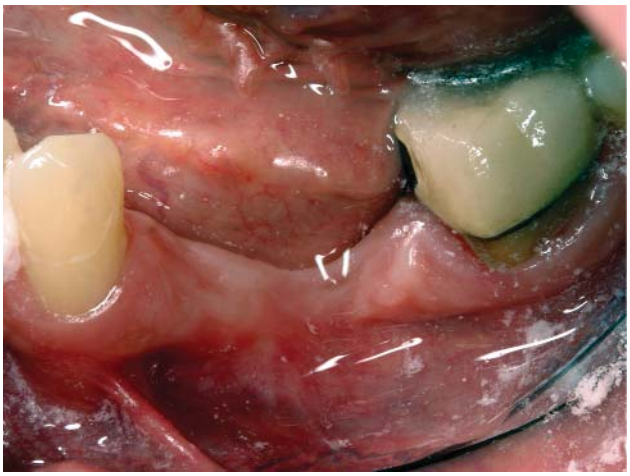

Pre-Op Buccal View

Pre-Op Occlusal View

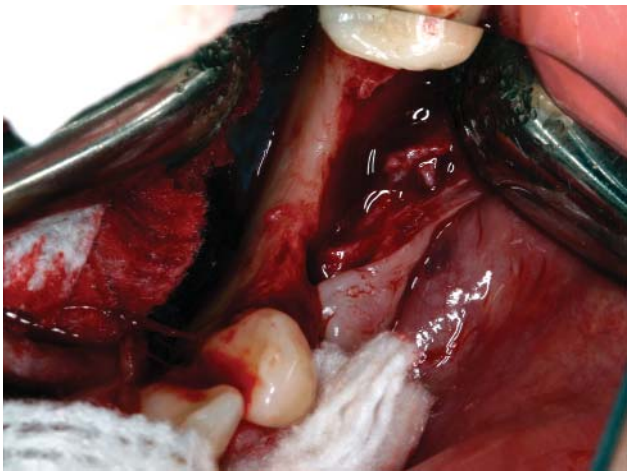

Mid-crestal incision, a mucoperiosteal flap is reflected buccally and lingually.

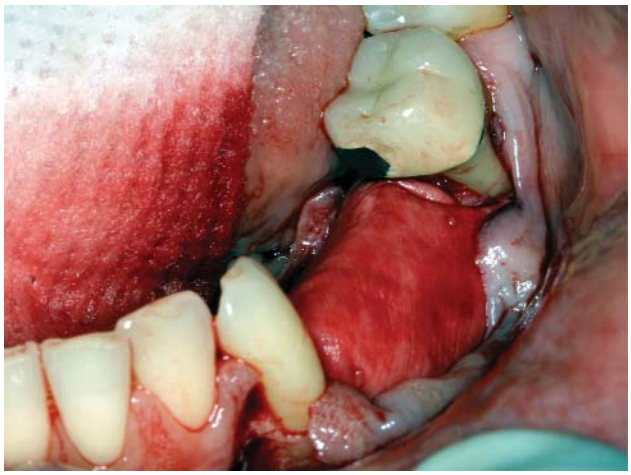

Collagen barrier membrane placement over Regenaform graft.

Buccal and Occlusal Views Six Months Post-Op

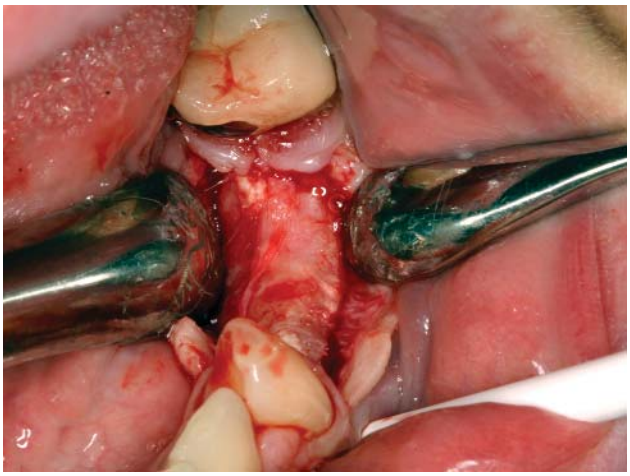

Re-entry Into Regenaform Grafted Site Six Months Post-Op

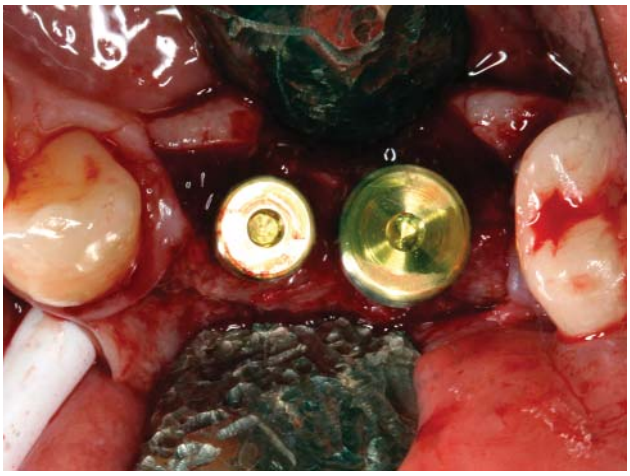

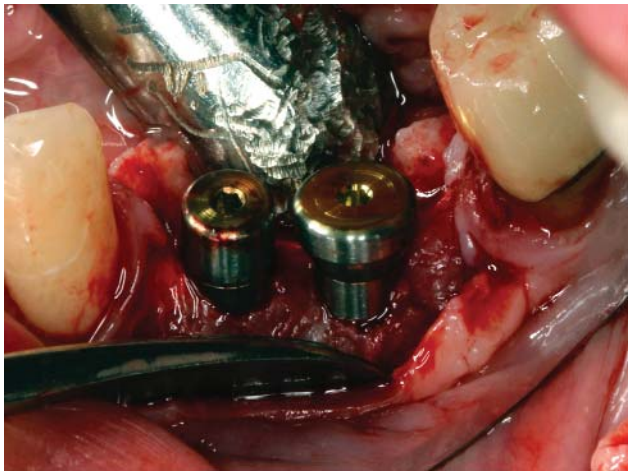

Occlusal and Buccal View of Implant Placement In Regenerated Bone

Exactech®

2320 NW 66th Court
Gainesville, Florida 32653
1-866-284-9690

www.exac.com

©2004 Exactech, Inc.
717-00-61 1104